

Compound odontoma in primary dentition- A case report

Metashi Singla^{1*}, Kanika Gupta Verma², Tanya Goyal³, Ashish Kakkar⁴, Lovejeet Ahuja⁵

¹PG Student, ²Associate Professor, ^{3,4,5}Senior Lecturer, Dept. of Pedodontics,

***Corresponding Author:**

Email: drsingla555@gmail.com

Abstract

The Odontome is a developmental anomaly of dental tissues. It is of two types; Compound and complex. Compound odontomas are two times more common than the complex odontomas and are more commonly seen in maxilla in the incisor-canine region. The complex odontomas are more seen in both the jaws commonly in premolar-molar region. These are rarely associated with primary teeth if present; they are usually of compound type. The purpose of this article is to present a case report of compound odontoma in the maxillary region of a 6 year old girl.

Keywords: Compound odontoma, Maxilla, Primary dentition, Anterior, Incisors.

Introduction

In 1867, Paul Broca coined the term Odontoma which was referred as any tumor of odontogenic origin.⁽¹⁾ These are the mixed type of odontogenic tumors, with functional differentiation of both epithelial and mesenchymal components as odontogenic cells which failed to obtain the normal state of morphodifferentiation, thus the enamel and dentin are usually laid down in an abnormal fashion. Odontomas are considered to be the hamartomatous malformation of ameloblasts and odontoblasts.⁽²⁾ There was no significant gender predilection. World health organization (WHO), defined it as an anomaly with well-formed individual tissue but occurring in disorderly pattern.⁽³⁾ They were classified on the basis of radiographic, morphological and microscopic features, and of two types; complex or compound odontomas. Compound odontomas consist of many separate, small, tooth-like denticles, present in an orderly fashion whereas a complex odontoma is an amorphous conglomeration of dental tissues consisting of enamel, dentin, cementum, pulp and enamel organ.⁽⁴⁾ The odontomas are slow growing commonly seen in second decade of life, are with expanding lesions which are usually asymptomatic and discovered on routine radiographic examinations. The odontomas are mostly associated with pathological changes such as delayed eruption, impaction, malpositioning of tooth, cystic formation, but rarely seen to be associated with the absence of one or more contiguous teeth.⁽⁵⁾ Odontomas are commonly seen in the permanent dentition rather than in primary teeth. Although, the etiology of odontoma is unknown, but many cases have been associated with infection, or genetics. They are often diagnosed, as they can cause over retention, delayed eruption, and impaction of both primary and permanent teeth. Most commonly, they are present in the bone, but may erupt into the oral cavity.⁽⁶⁾ The incidence of odontoma is rare in primary dentition, thus presenting a

case report of a patient with compound odontoma in primary dentition, who reported to our department.

Case Report

A six years old female patient with her guardians reported to the Department of Pedodontics, Surendera Dental College and Research Institute, Sriganganagar, Rajasthan, with a chief complaint of delayed eruption of her upper front teeth since 2-3 years. Her medical and family history was not relevant with no deleterious habits. Intraoral examination revealed unerupted maxillary deciduous incisor of right region i.e. 51 and a hard mass swelling in maxillary anterior right region (Fig. 1a and 1b). There was no history of pain and any other associated symptoms. On intraoral periapical and occlusal radiographic examination (Fig. 2 and 3) a calcified dental tissues, with radioopacities occurring in the maxillary right anterior region. An orthopantomogram (Fig. 4) revealed a predominantly radio-opaque mass similar in density with calcified dental tissues, with small radiolucencies located w.r.t 52 and congenital missing of 51 11 12 teeth. Considering the clinical and radiological presentations, a provisional diagnosis of compound odontome was made and the case was planned for surgical excision of compound odontoma under local anesthesia and removable partial denture wrt 11 and 12.

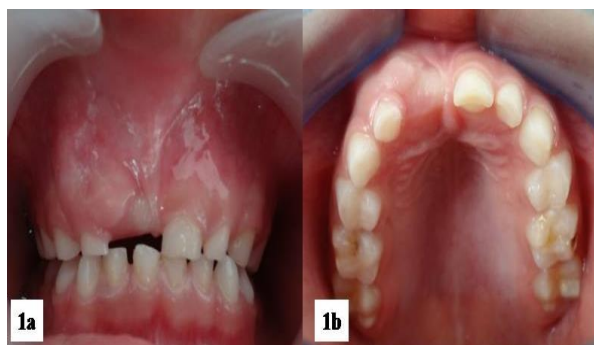

Fig. 1: a: Intraoral photograph showing unerupted maxillary deciduous right central incisor and a hard swelling in maxillary anterior right region

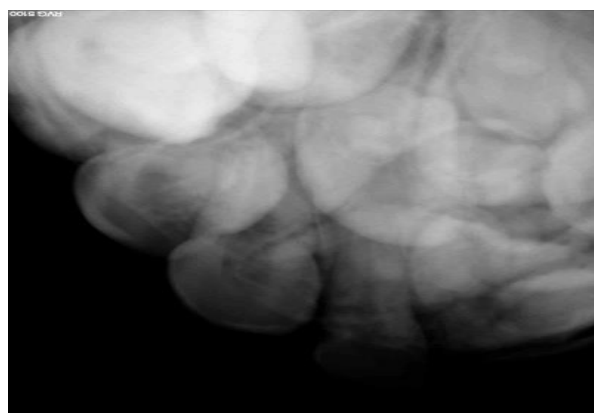


Fig. 2: Intraoral periapical radiograph showing a calcified dental tissues, located in the maxillary right anterior region

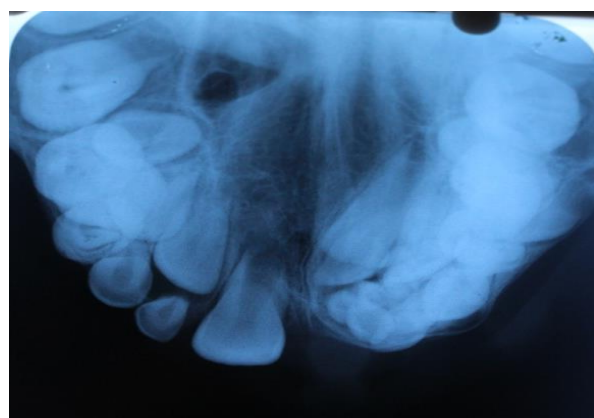


Fig. 3: Occlusal radiograph showing a calcified dental tissues, located in the maxillary right

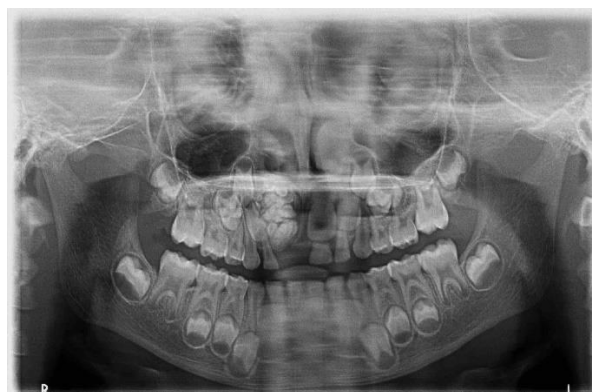

Fig. 4: An orthopantogram showing a predominantly radio-opaque mass similar in density with calcified dental tissues, with small radiolucencies located w.r.t 53 and congenital missing of 51 11 12 teeth

Discussion

In American and European population, Odontomas are the most common odontogenic tumor, but in India, their incidence is less. The less incidence can be due to two reasons- the first being under reporting of the cases; as most of the odontomas are symptomless and are discovered accidentally on routine radiographic investigations.⁽⁴⁾ Secondly, in India, patient do not seek medical consultation unless, they have discomfort or symptoms related to pathology.⁽⁷⁾ Odontomas are often seen in the permanent dentition and very rarely associated with the primary teeth. The compound odontoma is commonly detected at 14.8 years of age whereas complex odontoma at 16 years. Compound odontomas have equally distribution among males and females.⁽⁸⁾

Odontoma appears as an irregular radio-opacity or denticles surrounded by a radiolucency with or without a bony expansion, radiographically. Retained deciduous tooth can be seen associated with an unerupted permanent tooth. The patient is usually represented without any symptoms.⁽³⁾

In our case, compound odontoma was diagnosed accidentally on radiographic examination and the patient was asymptomatic. Clinically, the odontoma is indicated with retention or missing of primary tooth, unerupted permanent teeth, cortical bone expansion and displacement of tooth. Other case reports presented with symptoms that include lower lip paresthesia, frontal headache and swelling in the affected area, but associated pain is rare. Most authors agreed that the lesions appear more often in the maxilla, though some studies showed no distinction between the two jaws. In our case, the odontoma was located in the upper jaw, what is in accordance with the theory of many authors.⁽⁹⁾ Most common occurrence of odontomas is in the incisor-canine region, which is also seen in present case. Interestingly, both types of odontoma are seen

more frequently on the right side of the jaw than on the left, as observed in our case.⁽⁶⁾

Odontomas have been associated with trauma to primary dentition, with inflammatory and infectious processes, hereditary anomalies like Gardner syndrome, Hermann's syndrome etc., odontoblastic hyperactivity and alteration in the genetic components that control dental development.⁽¹⁰⁾ In present case, there was no associated syndromes or history of previous trauma to the patient.

Conclusion

We presented a case of missing primary teeth with compound odontoma which was found accidentally. To prevent the adverse effects of this anomaly, the authors stress upon the importance of routine use of panoramic radiographs for their early detection and management.

References

1. Gill NC, Yadav R. A rare case of complex odontoma associated with the root of an erupted mandibular primary incisor. *Indian J Oral Sci* 20014;5(2):95-100.
2. Yildirim-Öz G, Tosun G, Kiziloğlu D, Durmuş E, Şener Y. An Unusual Association of Odontomas with Primary Teeth. *Eur J Dent* 2007;1(1):45-9.
3. Kodali RM, Suresh BV, Raju PR, Vora SK. An Unusual Complex Odontoma. *J Maxillofac Oral Surg* 2010;9(3):314-7.
4. Patil S, Ramesh DSNV, Kalla. Complex odontoma: report of two unusual cases. *Braz J Oral Sci* 2012;11(4):1-7.
5. Sharma U, Sharmab R, Gulatic A, Yadavc R, Gaubaa K. Compound composite odontoma with unusual number of denticles – A rare entity. *Saudi Dent J* 2010;22(3):145-9.
6. Sreedharan S and Krishnan IS. Compound odontoma associated with impacted maxillary incisors. *Indian Soc Paediatr Prev Dent* 2012;30(3):275-8.
7. Lopez-Areal L, Donat FS, Lozano JG. Compound odontoma erupting in the mouth: 4-year follow-up of a clinical case. *J Oral Path Med* 1992;21(6):285-8.
8. Budnick SD. Compound and complex odontomas. *Oral Sur Oral Med Oral Path* 1976;42(4):501-6.
9. Cousins JW. A case of compound follicular odontoma. *Br Med J* 1908;1(2475):1352-4.
10. De Oliveira BH, Campos V, Marça S. Compound odontoma – diagnosis and treatment: three case reports. *Pediatr Dent* 2001;23(2):151-7.