

Assessment of immediate clinical outcome and short term prognosis of single tooth dental implants – A case series

Sandhya K^{1,*}, Bobby John², S. Mohan³

¹Senior Resident, ²Assistant Professor, ³Professor & HOD, Dept. of Oral & Maxillofacial Surgery, Govt. Dental College, Kottayam

***Corresponding Author:**

Email: ksandhya053@gmail.com

Abstract

Introduction: Dental implant is truly a revolution providing a solution to edentulism. The basis for modern dental implants is a biologic process called osseointegration where materials, such as titanium form an intimate bond to bone. The present study is concerned with assessing the short term treatment outcome of dental implants placed in the current clinical situation. Objectives: To evaluate hard tissue and peri-implant soft tissue changes around the implant and thus assess implant stability during the critical initial period.

Materials and Method: A case series study was conducted with twenty patients who presented to the Department of Oral and Maxillofacial Surgery for replacement of single missing tooth. The study was conducted from January 2013 to August 2014.

Results: The study group comprised of twenty patients with single missing tooth. There were twelve males and eight females in the study group, in the age group of 33.75 ± 8.8 years, ranging from 19 to 47 years. The parameters of all the implants evaluated were within Carl Misch's success criteria of implants. Mild radiolucency at the crestal portion and bone loss less than 3mm was present in some implants but was included in Misch's success criteria. None of the implants were mobile.

Conclusion: The uses of oral implants in the rehabilitation of partially and fully edentulous patients are widely accepted. Evaluation of implant stability and periimplant soft tissue changes of the sample group suggested that all the implants were stable during the critical initial period.

Keywords: Missing tooth, Dental implants, Stability, Peri-implant soft tissue, Clinical outcome, Prognosis, Success and failure.

Introduction

A dental implant is a surgical component that interfaces with the bone of the jaw or skull to support a dental prosthesis such as a crown, bridge, denture, facial prosthesis or to act as an orthodontic anchor. Dental implant is truly a revolution providing a solution to edentulism. Natural teeth and dental implants may look the same, feel the same, and even function in a similar way, but they are different. The most important differences are in the way they attach to the surrounding bone, their response to dental disease, their maintenance, and repair. Implant treatment requires precise planning to ensure that the implant is in the correct position and the crown, bridge or denture is of the correct design to produce a stable replacement for the missing teeth. The prerequisites to long term success of osseointegrated dental implants are healthy bone and gingiva.

Implants had their beginning around the middle of the twentieth century. In 1940s Dahlse⁽¹⁾ introduced sub periosteal implants. But the long term results of subperiosteal implants were inadequate. The concept of osseointegration was first put forth by Per-Ingvar Branemark⁽²⁾ in the year 1952. He discovered that bone can integrate with titanium implants. This phenomenon was termed as osseointegration based on the Latin word 'os' which means bone and 'integrate' which means to make whole. From 1993 till now, single tooth implants are considered the most successful method of tooth replacement. Schmitt (1993)⁽³⁾ conducted a study to test the efficacy of single-implant support for crowns to

replace missing single teeth. Multiple studies were also conducted by Carlson (1994),⁽⁴⁾ Becker (1995)⁽⁵⁾ and Henry (1996)⁽⁶⁾ on single tooth implants and considered it as a successful method for tooth replacement. Apart from single tooth, implants are also used for multiple tooth replacement with fixed partial dentures or complete dentures.

However many literatures^(7,8) have reported the drawbacks associated with conventional dental implant surgery. Bone resorption of varying degrees almost always occurs in the crestal area of the alveolar bone. Poor quality of bone in maxilla and machined surface lead to implant failure.⁽⁷⁾ Scott Froum⁽⁸⁾ suggested that implants placed in posterior region has high failure rate compared to implants placed in the anterior region. Reduced bone height, poorer bone quality, and at the same time exposure to greater occlusal loads than the anterior regions of the mouth led to an increased chance of implant failure in the posterior region. Caterina Venuleo⁽⁹⁾ conducted a radiographic follow up study to assess long term bone level stability of short implants. Failure in osseointegration can also lead to implant failure.⁽¹⁰⁾ The answer to the question of what constitutes success in implant dentistry remains complex. The success of dental implants depends on the site of implant, oral and general health of the patient, skill and judgment of the surgeon and the type of implant placed.

Dental implants are now a routine treatment option for replacing missing teeth. Norowski Jr. P.A. et al⁽¹¹⁾ has reported that the survival rate for an implant today

is around 89% over a period of 10-15 years though the dental infection risk may be as high as 14%. The risk of peri-implantitis is higher in the first months after implantation. Recently with newer hydroxyapatite and other osteoconductive materials the success rate is increasing from 85% to nearly 100%.⁽¹²⁾

The present study is concerned with assessing the short term treatment outcome of dental implants placed in the current clinical situation. This will make us aware of the merits and demerits in the present treatment procedures and to promote further research and treatment standards so as to ensure a long term success in the near future.

Patients and Methods

The aim of the study was to Assess implant stability during the critical initial period. Patients reporting to our hospital from January 2013 – August 2014 with single missing tooth were included in the study. The patients were enrolled in the study as per the following selection criteria:

Inclusion Criteria

- Oral cavity with generalized probing depth of less than 3 mm.
- Minimum of 2 mm of attached gingival at the implant site.
- Edentulous area with no signs of infection.
- Minimum of 9 mm of bone height available from the crest of edentulous ridge to the opposing landmark.
- Minimum bone width of 5 mm between the facial and lingual cortical walls at the implant site.
- Adjacent tooth at least 1.5 mm away from the implant site.

Exclusion criteria: Patients with co morbidities such as diabetes mellitus, cardiovascular, CNS, hepatic, respiratory, bleeding disorders were excluded from the study. Patients with a history of radiation therapy and also pregnant and post-menopausal women were excluded from the study. Patients with smoking habit were also not included.

The following parameters were evaluated (Table 1).

Table 1: Objectives of the study

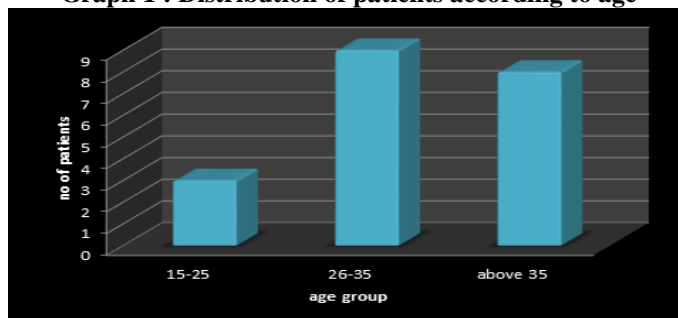
Objective	Outcome	Method of measurement of outcome
Implant stability	Crestal bone loss	Radiographic evaluation using intraoral periapical radiograph
	Implant mobility	Periotest method
	Pain	Wong-Baker Faces scale
	Radiolucency	Radiographic evaluation using Intraoral Periapical radiograph
Periimplant soft tissue change	Probing depth	Clinical probing using plastic probe with markings
	Bleeding on probing	Clinical probing using plastic probe with markings

Patients were evaluated with Digital intraoral periapical radiograph taken with paralleling technique in the following periods - Immediate post-operative radiograph after the flap closure, after 3 months at the second stage of surgery, followed by review at 3 months and 6 months after loading. Statistical analysis was done with SPSS statistics software version 20 using proportions, percentage and appropriate tabulation and analyzing with chi square test (X^2).

Results

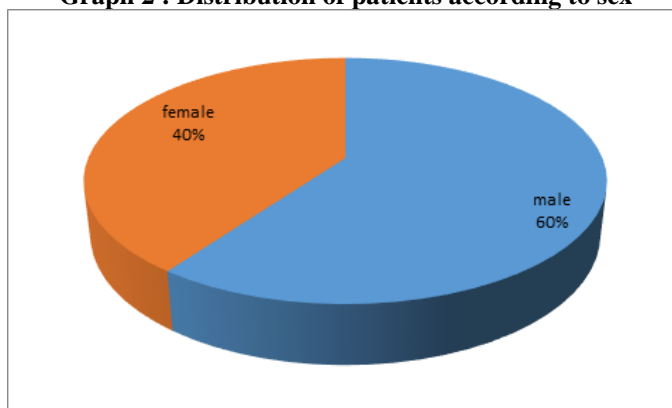
The study group comprised of twenty patients with single missing tooth. There were twelve males and eight females in the study group, in the age group of 33.75 ± 8.8 years, ranging from 19 to 47 years. Graph 1 shows age group distribution and Graph 2 shows sex distribution.

Graph 1 : Distribution of patients according to age



The maximum number of patients were between age group 26 – 35.

Graph 2 : Distribution of patients according to sex



Crestal bone loss was less than 1.5 in 70% of the cases. 6 patients had crestal bone loss between 1.5 to 2. Squared periotest value for all the 20 implants was less than 4 and hence was considered as fixed. Only a single patient reported mild pain during the immediate post-operative recall visit which was subsided with analgesics. Patient was symptom free during all the further follow up reviews. Fifteen patients had slight radiolucency around the crestal portion during the final follow up. Radiolucency was not detected at the crestal portion in the remaining five patients. The probing depth was stable in eight patients on all the follow ups. 12 patients had a change in probing depth; however the value was only less than 3mm. Soft tissues surrounding the implants were healthy and hence 90 percent of cases had no bleeding on probing. A point of bleed was noted in two cases on third follow up.

The associations between different variables were done using chi-square test. p value less than 0.05 was considered as significant. There were more male patients with bone loss less than 1.5mm. However there was no significant association between sex and crestal bone loss as p value is 0.550 with a chi-square value of 0.357. The two patients with a point of bleed on probing were males but there was no significant association between gender and bleeding on probing (p value 0.224).

The association between age group and probing depth was significant with a p value of 0.05 and chi-square value of 5.706 (Table 2, 3).

Table 2: Age group Vs Probing depth

		Probing depth		Total
		Stable probing depth	Probing depth less than 3	
Age group	15-25	3	0	3
	25-35	2	7	9
	35-50	3	5	8
Total		8	12	20

Table 3: Chi square value - Age group Vs Probing depth

		value	df	p value
Pearson square	chi	5.706	2	0.05

The clinical parameter of bone loss, bleeding on probing was compared with the actual crestal bone loss. The 13 patients who had no bleeding on probing had only crestal bone loss less than 1.5mm. One patient with crestal bone loss less than 1.5 had bleeding on probing. Though clinically there is an association between bleeding on probing and crestal bone loss statistically there was no significant association as p value was 0.515. The single patient with score one in Wong-Baker faces scale was evaluated for crestal bone loss, radiolucency and peri-implant soft tissue changes. Crestal bone loss was between 1.5-2 mm. But as the p value (0.117) was not significant it is considered as there is no significant association between the pain experienced by the patient and the crestal bone loss. Similarly the association between pain and radiolucency was not statistically significant (p value 0.554). Fig. 1- 8 shows steps in implant placement.

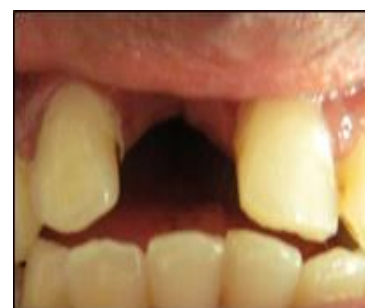

Fig. 1: Site for implant placement

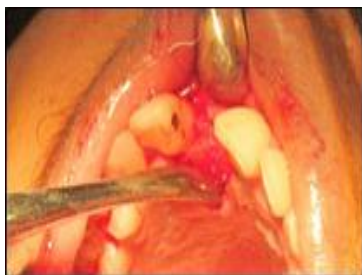

Fig. 2: Mucoperiosteal flap reflected

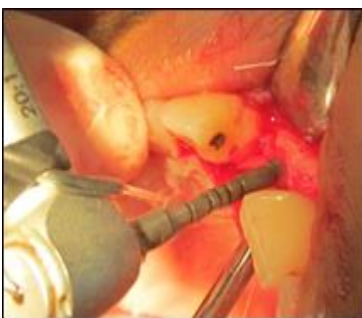

Fig. 3: Use of pilot drill

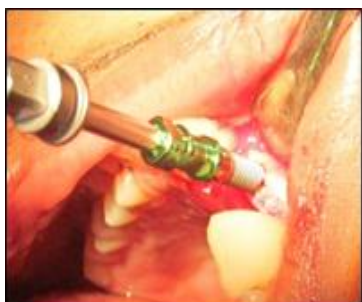

Fig. 4: Insertion of implant fixture

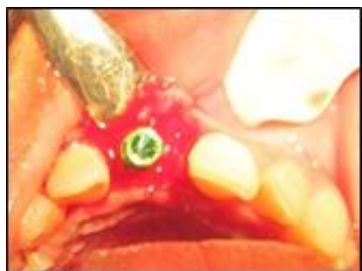

Fig. 5: Implant fixture inserted

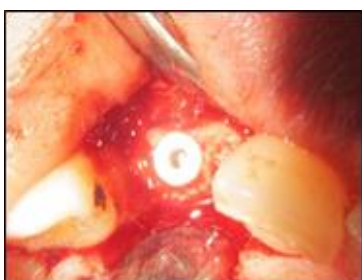

Fig. 6: Cover screw placed

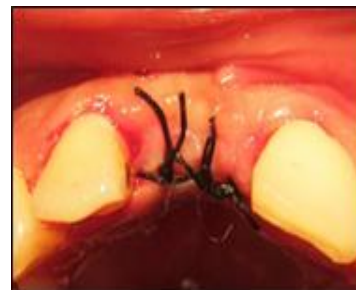

Fig. 7: Sutured site

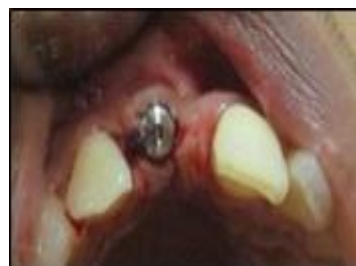

Fig. 8: Review after one week

Discussion

The immediate clinical outcome and prognosis of dental implants are dependent on various parameters such as implant mobility, pain, crestal bone loss, radiolucency around the implant and peri-implant soft tissue changes. Similar to natural tooth there exist a range from health to disease for implants. The primary criteria for assessing implant quality or health are pain and mobility. The presence of either one greatly compromises the implant and removal usually is indicated. Routine probing depths are not suggested in the absence of other signs or symptoms and may be related to the presence of local disease or pre-existing gingival thickness before the implant was inserted. Bone loss is most often evaluated with radiographs, which only monitor the mesial and distal marginal bone next to the implant.⁽¹³⁾ Despite high success rate with endosseous titanium implants, failures unavoidably occur. At an early stage, lack of primary stability, surgical trauma, peri-operative contamination and occlusal overload seem to be the most important causes of implant failure.⁽¹⁰⁾ Hence as done in the present study assessment of implant stability during the initial period helps in determining the long term prognosis.

The bone quality in different age groups can affect implant prognosis. Hadi S A⁽¹⁴⁾ suggested that patients with increased age will have more systemic health problems, but there is no scientific evidence correlating old age with implant failure. Although Salonen et al (1993)⁽¹⁵⁾ stated that advanced age was a possible contributing factor to implant failure; other reports have showed no relationship between old age and implant failure. Jaffin and Berman,⁽¹⁶⁾ in their 5-year analysis, reported that as many as 35% of all implant failures occurred in type IV bone due to its thin cortex, poor medullary strength, and low trabecular density.

Unfortunately, the diagnosis of type IV bone is usually made during implant site preparation. Although periapical radiographs offer some diagnostic help in identifying type IV bone, they may be deceiving because a thick buccal or lingual plate may obscure the soft nature of medullary bone. In the present study there was no type III or type IV bone, and hence all the implants were successful as far as the bone type was considered.

Ioannis K. Karoussis⁽¹⁷⁾ reported after a 10 year prospective study that patients with implants replacing teeth lost due to chronic periodontitis demonstrated lower survival rates and more biological complications than patients with implants replacing teeth lost due to reasons other than periodontitis. Hence full mouth prophylaxis done prior to implant placement in all patients also facilitated the comparison of prognosis of the implants placed. Except in two patients the peri-implant soft tissue was healthy throughout the follow up period. In the two patients in whom mild bleeding on probing was noted underwent oral prophylaxis and maintenance instructions, after which no bleeding was noted.

The longevity of dental implants is highly dependent on integration between implant components and oral tissues, including hard and soft tissues. Initial breakdown of the implant-tissue interface generally begins at the crestal region in successfully osseointegrated endosteal implants.⁽¹⁸⁾ After the first year of function, crestal bone loss to or beyond the first thread of titanium screw implants, characterized by "saucerization," is often observed radio graphically around certain implant types. Crestal bone loss at the implant site was less than 3mm in all the patients in the study group. Of this 70% had crestal bone loss only less than 1.5mm. According to Carl Misch implant quality scale this was considered as implant success.

Albrektson et al⁽¹⁹⁾ (1986) proposed the criteria for successful integration of dental implants. Success criteria included that implants display immobility, absence of peri-implant radiolucency, and marginal bone loss not exceeding 1.5mm after the first year of loading and up to 0.2mm yearly. Of these, a lack of mobility is of prime importance and any detected mobility indicates implant failure. Loosening is cited as the most common reason for implant removal. According to Carl Misch implant quality scale, implants with a squared periotest value greater than 10 was considered as failure. In this study all the implants were fixed with a squared periotest value less than 4.

After each surgical stage, some degree of pain and discomfort can occur. Many patients find that pain is one of the first things they notice after getting an implant, once the anesthesia wears off. There can also be soreness in the area where the implant is being placed, as well as in the jawbone surrounding this area. Drilling a hole into the jawbone does cause some discomfort for about a week after the procedure.

Depending on where the implant is located, this pain may extend to the cheeks, the chin, or underneath the eyes. In this study only a single patient reported mild pain during the immediate post-operative recall visit which subsided with analgesics. Patient was symptom free during all the further follow up reviews.

Radiolucency around the implant is considered as failure according to Carl Misch implant quality scale. In this study none of the implants had radiolucency throughout implant. Few patients had a mild radiolucency at the crestal portion of the implant. The radiolucency was not progressing during the follow up period. According to Albrektson et al.⁽¹⁹⁾ implant success criteria included radiography that does not demonstrate evidence of peri-implant radiolucency.

The probing depth was stable in eight patients on all the follow ups. 12 patients had a change in probing depth, however the value was only less than 3mm. Gerber et al⁽²⁰⁾ demonstrated that a significantly deeper mean probing depth at implant sites compared with tooth sites was found irrespective of the probing pressure applied. Though probing pressure was not measured in the study, implants had only a probing depth less than 3mm.

Point of bleed was noted in two patients at the mesial margin during a follow up visit. Gerber et al⁽²⁰⁾ demonstrated that 0.15 N might represent the threshold pressure to be applied to avoid false positive bleeding on probing (BOP) readings around oral implants. Author concluded that probing around implants demonstrated a higher sensitivity compared with probing around teeth. Ingvar Ericsson⁽²¹⁾ observed that the resistance offered by the gingiva to probing was greater than that offered by the peri-implant mucosa, and consequently the probe penetration became more advanced at implants than at teeth. In the present study probing pressure was not measured. Bleeding on probing tendency was calculated by the same person with a plastic probe with markings. Hence the point of bleed noted in two patients during a follow up visit cannot be taken into account. Oral prophylaxis and proper oral hygiene instructions were given to these patients and since then no bleeding tendency was seen.

Age group and probing depth demonstrated a significant association. Though probing depth was only less than 3mm, as age group increased probing depth increased. In this study statistically there was no association between the parameters. This could be due to reduced sample size and follow up for a short period of time. Nine months follow up is too short to predict the success of dental implants. Further studies are required to evaluate the long term prognosis and clinical outcome of implants.

Conclusion

The study concluded that all the implants placed in the current clinical scenario were successful for until six months after loading. A more comprehensive study

including control groups with a larger sample size and longer study period may be required to validate the accuracy of the results.

References

1. Zwerger S Abu-Id MH, Kreusch T. Long-term results of fitting subperiosteal implants: report of twelve patient cases. *Mund Kiefer Gesichtschir*; 2007 Dec;11(6):359-62. German.
2. K. Harshakumar R, Ravichandran, Vivek. V. Nair, Aswathi Krishnan. Osseointegration. *Indian J Dent. Scienc*; March 2014;1(6).
3. Schmitt A, Zarb G A. The longitudinal clinical effectiveness of osseointegrated dental implants for single-tooth replacement. *Int J Prosthodont*. 1993 Mar-Apr;6(2):197-202.
4. Carlson, Bill, E. Carlsson, Gunnar. Prosthodontic Complications in osseointegrated dental implant treatment. *Int J Oral Maxillofac Impl*. 1994;9.
5. Becker W, Becker B E. Replacement of maxillary and mandibular molars with single endosseous implant restorations: a retrospective study. *J Prosthet Dent*. 1995 Jul;74(1):51-5.
6. Henry PJ, Laney WR, Jemt T, Harris D, Krogh PH, Polizzi G, Zarb GA, Herrmann I. Osseointegrated implants for single-tooth replacement: a prospective 5-year multicenter study. *Int J Oral Maxillofac Impl*. 1996 Jul-Aug;11(4):450-455.
7. Hua ling sun, cui huang, Yan Ru Vu. Failure rates of short dental implants (< 10mm) and factors influencing their failure: a systematic review. *Int J Oral Maxillofac Impl*. 2011;26:816-825.
8. An alternative to conventional dental implants: short implants By Scott Froum, surgical restorative resource (web search www.surgicalrestorative.com).
9. Caterina Venuleo, Sung-Kiang Chuang, Meghan Weed, Serge Dibart Long term bone level stability on Short Implants: A radiographic follow up study. *J Oral Maxillofac Surg*; 2008;7(3).
10. Hadi SA, Ashfaq N, Bey A, Khan S. Biological factors responsible for failure of osseointegration in oral implants review article. *Biology and Medicine Special Issue* 2011;164-170.
11. Norowski, PA, Bumgardner. Biomaterial and antibiotic strategies for peri-implantitis: a review. *Biomed Mater Res B Appl Biomater*. 2009;88(2):530-43.
12. Judith A porter, Anthony Von Fraunhofer. Success or failure of dental implants: A literature review with treatment considerations. *Peer -reviewed J of academy of general dentistry* Aug 2005.
13. Carl E. Misch, Morton L. Perel, Hom-Lay Wang Implant Success, Survival, and Failure: The International Congress of Oral Implantologists (ICOI) Pisa Consensus Conference
14. Krim Mohamed. Biological factors responsible for failure of osseointegration. (Web search www.omicsonline.com).
15. Salonen MA, Oikarinen K, Virtanen K, Pernu H, 1993. Failures in the osseointegration of endosseous implants. *Int. J. Oral Maxillofac Impl*. 2009 Jan;8:92-7.
16. Jaffin RA, Berman CL. The excessive loss of Branemark fixtures in type IV bone: a 5-year analysis. *J Periodontol*. 1991 Jan;62(1):2-4.
17. Luterbacher Tschudin. On the management of some technical and biological complications in implant prosthodontics 2009 Lincentiate thesis web search (www.dissertations.se).
18. Adell R, Lekholm U, Rockler B, Branemark PI. A 15-year study of osseointegrated implants in the treatment of the edentulous jaw. *Int J Oral Surg*. 1981 Dec;10(6):387-416.
19. T. Albrektson, G. Zarb, P. Worthington, and A. R. Eriksson. The long-term efficacy of currently used dental implants: a review and proposed criteria of success. *Int. J Oral Maxillofac Impl*. 1986;1:11-25.
20. Gerber JA, Tan WC, Balmer TE, Salvi GE, Lang NP. Bleeding on probing and pocket probing depth in relation to probing pressure and mucosal health around oral implants. *Clin Oral Impl Res*. 2009 Jan;20(1):75-8.
21. Ingvar Ericsson, Jan Lindhe. Probing depth at implants and teeth: an experimental study in the dog. *J Clin. Periodontol*. October 1993;20:9:623-627.