

## Glandular odontogenic cyst: a clinically challenging pathology

Heena Sayed<sup>1,\*</sup>, Aatif Sayed<sup>2</sup>, Amit Sangle<sup>3</sup>

<sup>1</sup>Resident, <sup>2</sup>Senior Lecturer, <sup>3</sup>Professor, Dept. of Oral & Maxillofacial Surgery, M.A. Rangoonwala Dental College, Pune, Maharashtra

**\*Corresponding Author:**

Email: hee.sayed@hotmail.com

### Abstract

Glandular odontogenic cyst (GOC) is an uncommon developmental odontogenic cyst of the jaw with a relative frequency between 0.012-1.3%. GOC is very rare and has an unpredictable and potentially aggressive behaviour. Generally this cyst is encountered in the anterior areas of the mandible and is more common with a wide age range, the mean age being 49.5 years, and has a tendency to recur. GOC is often misdiagnosed because of its overlapping clinical and histopathological features with that of other odontogenic cysts such as lateral periodontal cyst (LPC) and central low-grade Mucoepidermoid Carcinoma. Here, we present a case of GOC in a 43 yr old male patient in the right mandibular posterior region treated by enucleation and chemical curettage with Carnoy's solution.

**Keywords:** Glandular odontogenic cyst, Developmental cyst, Lateral periodontal cyst, Mucoepidermoid carcinoma, Carnoy's solution

### Introduction

The Glandular Odontogenic Cyst (GOC) is a rare developmental cyst of the jaw, having an odontogenic origin. It was first described by Sir David G. Gardener et al in 1988 as a distinct entity and due to its unusual histopathological features and biological behaviour, it was named as Glandular odontogenic cyst.<sup>(1)</sup> It was initially named as "Sialo odontogenic cyst" by Padayachee and Van-wyk in 1987 wherein they reported two cases that were similar to botryoid odontogenic cyst, but with a glandular element, hence the name was suggested.<sup>(2)</sup> They indicated the typical feature of this cyst that it is intrabony and radiologically multilocular, multicystic with the cystic spaces lined by non-keratinized epithelium similar to reduced enamel epithelium, with epithelial thickenings or plaques; that the mucous and cylindrical cells form an integral part of the epithelial component and that the mucinous material within the cystic spaces is a prominent feature. Its name was changed to GOC by Gardner *et al.* a year later because of the lack of evidence of salivary gland origin, and the term was later adopted by the World Health Organization (WHO).<sup>(3)</sup> It shows many features similar to, and occurs in the same location as lateral periodontal cyst, and so it is considered as a variant by some authors.<sup>(4)</sup> In 1991, Sadeghi et al suggested that mucoepidermoid odontogenic cyst would be the term most descriptive of the lesion due to the presence of both, secretory elements and stratified squamous epithelium.<sup>(5)</sup> However, this name would be confused with mucoepidermoid carcinoma, and hence disagreed by Shear in 1992.<sup>(6)</sup> There is very much similarity between the histopathological features of GOC and low-grade central mucoepidermoid carcinoma.<sup>(7)</sup>

Initially, odontogenic cysts were noted to be lined with clear cells and were accepted as glandular prosoplasia from the squamous cell linings having no

special clinical significance. However, since 1990, it has been reported that these jaw cysts are identified with either numerous mucinous glandular elements in the lining or complete glandular lining.<sup>(8)</sup> These cysts have a more aggressive behaviour, larger in size and a tendency to recur if not adequately excised. The rate of recurrence ranges from 21-55% depending on the different treatment options.<sup>(9)</sup> So, some authors have suggested treatments that are even more aggressive than enucleation and curettage for most other cysts. These treatment options include marginal resection, peripheral ostectomy and partial jaw resection.<sup>(10)</sup> In the studies carried out previously, recurrence was seen either in the form of GOC itself or as low-grade mucoepidermoid carcinoma.<sup>(8)</sup> From these factors, it is clear that GOC represents one of the three possibilities- (i) a true odontogenic cyst of glandular origin from either entrapped salivary gland primordia or undifferentiated primitive epithelial rests that differentiate into glandular epithelium; (ii) an odontogenic cyst of primordial origin where the epithelial lining further undergoes differentiation into glandular epithelium; or (iii) a low-grade mucoepidermoid carcinoma that forms an initial single cystic space instead of the usual multicystic spaces.<sup>(11)</sup>

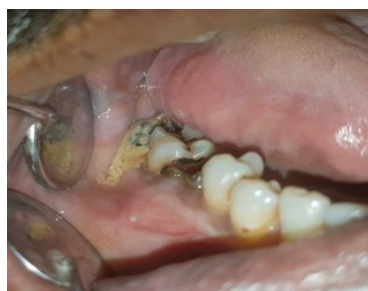The purpose of this case report is to discuss how the clinical, radiographic and histological features can aid in the final diagnosis of GOC which is otherwise very challenging on the basis of clinical examination and also its treatment involving chemical therapy following its complete enucleation.

### Case Report

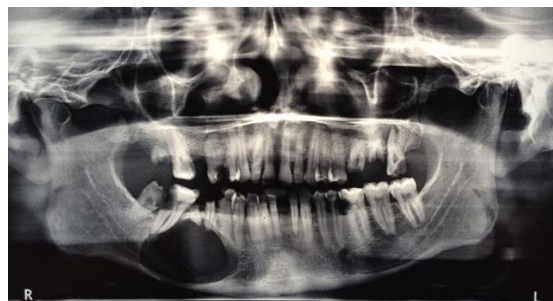A 43-years old male patient reported to our institute with a chief complaint of a painless swelling in the lower right back tooth region since 1 month, which was small and gradually increased in size over the past

17 days. He had a history of diabetes since 5 years for which he was on medication. He was also diagnosed with pancreatitis and oesophageal varices for which he was treated. He was a chronic alcoholic and had a habit of smoking 7 cigarettes a day. On local extra-oral examination, the swelling extended from the corner of the mouth antero-superiorly up to the inferior border of the mandible inferiorly and up to the antegonial notch posteriorly measuring approximately 3.5\*2.5 centimetres. On palpation, the swelling was non-tender, bony hard and non-fluctuant. The intraoral examination revealed a vestibular swelling in the right mandibular buccal sulcus extending from mesial aspect of second premolar up to the distal aspect of second molar. No lingual bony expansion was appreciated. The overlying mucosa was intact and smooth. Also, the associated second molar was grossly decayed and root stump was seen with first and third molar teeth. On percussion, they were non-tender. On palpation, the swelling was firm, non-tender, non-fluctuant and non-pulsatile [Fig. 1]. Based on these clinical signs, a provisional diagnosis of radicular cyst was given with a differential diagnosis of odontogenic keratocyst.

Radiographic examination revealed a unilocular radiolucency associated with first molar tooth extending up to the inferior border of the mandible with a well-defined radiopaque border. The distal root of the first molar appeared to be resorbed and that of the adjacent second molar tooth were displaced [Fig. 2]. A cone beam computed tomographic imaging was done to locate the extent of the lesion and its proximity to the inferior alveolar neurovascular bundle. Considerable expansion and thinning of the buccal cortical plate was appreciated. Based on the above clinical and radiographic features, we established a final diagnosis of Radicular Cyst and proceeded with the surgical treatment after adequate control of his blood sugar level.

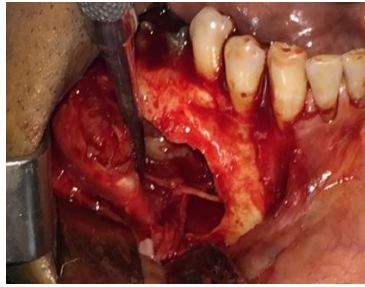


**Fig. 1: Intra-oral vestibular swelling in relation to 45-47**

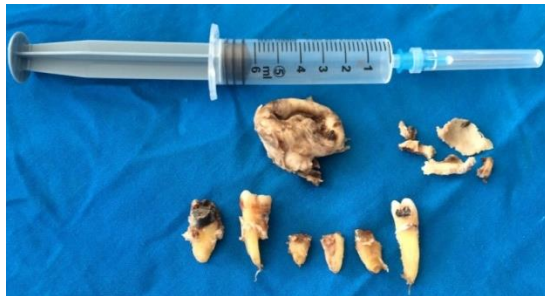

**Fig. 2: Panoramic radiograph showing a well-defined, unilocular, radiolucent lesion associated with 46 and displaced roots of 47**

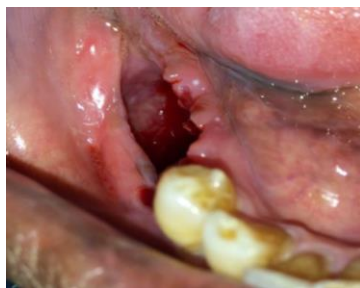The patient was operated under general anaesthesia with all aseptic measures. A crevicular incision along with an anterior releasing incision was given and a triangular mucoperiosteal flap was raised. The bony window was expanded through the fenestration already present and the cyst was enucleated from the mesial aspect going distally. The cystic lining was carefully separated from the inferior alveolar neurovascular bundle and the nerve was preserved [Fig. 3]. This was followed by extraction of second premolar, and all three molar teeth and removal of interdental bony spicules. The bony margin was smoothed with a bone file. In order for the cystic cavity to receive a chemical therapy, the neurovascular bundle was deflected distally with the help of a suture tie and a roller gauze soaked in freshly prepared Carnoy's solution was placed in the cystic cavity for around 3 minutes while simultaneously isolating the nerve with instrumentation to avoid contact. After complete irrigation of the site, the cystic cavity was packed with absorbable gelatin and a roller gauze soaked in betadene ointment. The flap was repositioned and closure was done with 3-0 vicryl after leaving a small gap for further changing the betadene dressing during the follow-up phase. This betadene ointment dressing was replaced every 5-7 days post-operatively for one and a half month after which the cavity was merely irrigated and allowed to heal [Fig. 5]. The specimen was removed in a single piece and was sent for histopathologic evaluation [Fig. 4]. The histological examination of the surgical specimen suggested the lesion to be a Glandular Odontogenic Cyst. After three months of regular follow-up, a panoramic radiograph was taken which revealed considerable bone healing and resolution [Fig. 6]. The patient was recalled frequently for follow-up and a year later, examination showed no signs of recurrence.



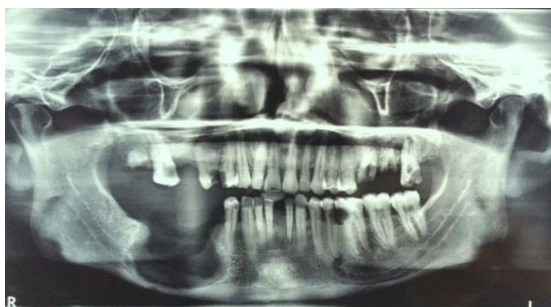**Fig. 3:** Cystic lining carefully separated while preserving the nerve



**Fig. 4:** Gross specimen- lesion enucleated in a single piece, bony fragments and extracted teeth

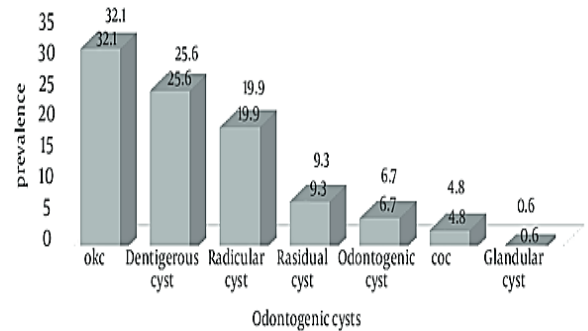


**Fig. 5:** 1 ½ month post-operative showing considerable healing



**Fig. 6:** 3 months post-operative panoramic radiograph showing evidence of bone healing

**Table 1:** The prevalence of odontogenic cysts in the oral cavity



**Discussion**

Glandular odontogenic cyst (GOC) is an uncommon odontogenic cyst of the jaw with approximately 116 cases reported in literature so far. Amongst all the cysts, it has a rate of occurrence of only 0.012-1.3% [Table 1].<sup>(12)</sup> It is difficult to differentiate this lesion from other odontogenic cysts of the jaw, and so a histopathological examination gives a clearer picture. However, significant overlap exists between GOC and central mucoepidermoid carcinoma histologically. So, the presence of superficial cuboidal cells, ciliated cells, epithelial whorls and intraepithelial microcyst or duct-like structures can help it differentiate from the latter.

In the case discussed here, since the patient had carious teeth present in that region, it led us to the assumption that the cyst could be inflammatory in nature. Radicular cyst is the most common odontogenic cyst of the jaw.<sup>(4)</sup> It is the result of pulp necrosis following caries with an associated periapical inflammatory response in most of the case. So, it is the result of chronic inflammatory process and occurs over a period of time. It rarely causes resorption of the roots of the affected tooth and expansion of the cortical plates.

Glandular odontogenic cyst can be solitary but usually multilocular, probably derived from the dental lamina. It occurs in a wide age range and has a slight male predilection. Clinically, the mandibular anterior region is the most common site of occurrence in 85% cases and especially crosses the midline, and presents as a slowly progressing asymptomatic swelling. Its size can vary from as small as 1 cm in diameter to large destructive lesions that may involve most of the jaw. The smaller ones are usually asymptomatic. Radiographic features denote the lesion as a unilocular and more often, a multilocular radiolucency with a well-defined radiopaque border.<sup>(13)</sup> However, the clinical and radiographic findings of this lesion are usually varied and often not pathognomonic.<sup>(12,14)</sup> GOC is a relatively aggressive lesion, having a high tendency for erosion or perforation of the cortical plates and also a high tendency to recur.<sup>(15)</sup> These features were

observed in the present case, in which a unilocular radiolucency with well-defined radiopaque border was appreciated in the mandibular posterior region, in the panoramic radiograph.

Due to similarities in microscopic characteristics between GOC and lesions such as botryoid cyst, radicular and dentigerous cysts with mucous metaplasia and more importantly low-grade mucoepidermoid carcinoma, it is difficult to make a definitive diagnosis. Nevertheless, the diagnosis of GOC had to be based on the mandatory presence of the five major features. These are squamous epithelium, varying thickness, cuboidal eosinophilic (“hobnail”) cells, mucous (goblet) cells and intraepithelial glandular or duct-like structures. The histological diagnosis of the present case fulfilled these histopathological criteria for GOC.

Taking into consideration the invasive potential and high recurrence rate associated with conservative treatment of the cysts, the surgical management of this lesion was carried out by enucleation followed by chemical therapy with Carnoy’s solution. Carnoy’s solution is often used as a complementary treatment of those lesions with high recurrence rates and involves the treatment of the remnant surgical bed.<sup>(16)</sup> The application of Carnoy’s solution promotes a superficial chemical necrosis and is intended to reduce the recurrence rates. Though the inferior alveolar neurovascular bundle was preserved in our case, the safety of the application of Carnoy’s solution over this plexus has been reported in literature with low and transient neural morbidity.<sup>(17)</sup>

## Conclusion

It is important to differentiate GOC from other odontogenic cyst of the jaw. Since they have a potential ability to recur, it should be treated appropriately/adequately. This treatment can be planned successfully only if it is well differentiated from the group of similar pathologies discussed earlier. This can be quite challenging for the surgeon as well as the pathologist.

## References

- Gardener DG, Kessler HP, Morency R, Schaner DL. The glandular odontogenic cyst: an apparent entity. *J Oral Pathol.* 1988;17:359-66.
- Padayachee A, Van Wyk CW. Two cystic lesions with features of both the botryoid odontogenic cyst and the central mucoepidermoid tumour: Sialo-odontogenic cyst? *J Oral Pathol* 1987;16:499-504.
- Kaplan I, Gal G, Anavi Y, Manor R, Calderon S. Glandular odontogenic cyst: Treatment and recurrence. *J Oral Maxillofac Surg* 2005;63:435-41.
- Shafer WG, Hine, Levy. *Shafer’s textbook of Oral Pathology.* 5th ed. India: Elsevier; 2005.
- Sadeghi EM, Weldon LL, Kwon PH, Sampson E. Mucoepidermoid odontogenic cyst. *Int J Oral Maxillofac Surg* 1991;20:142-3.
- Shear M. *Paul Speight Cyst of the Oral and Maxillofacial Region.* 3rd ed. Butterworth Heinemann, 1992.
- Sudeendra Prabhu, Rekha K, Kumar GS. Glandular odontogenic cyst mimicking central mucoepidermoid carcinoma.
- Shear M. *Cysts of the Oral Region.* 3rd ed. Mumbai: Varghese Publishing House; 1992.
- Boffano P, Cassarino E, Zavattero E, Campisi P, Garzino-Demo P: Surgical treatment of glandular odontogenic cysts. *J Craniofac Surg* 21:776e780, 2010.
- Oliveira Neto P, Sávio E, Bezerra TP, Avelar RL, Raimundo Rde C, Gomes AC, et al: Anterior mandibular swelling. *J Oral Maxillofac Surg* 68:436e441, 2010.
- Mark RE, Stern D. *Oral and maxillofacial pathology. A rationale for diagnosis and treatment.* 2nd ed, Vol. New Delhi: Quintessence Publishing co, Inc; 2012.
- Shen J, Fan M, Chen X, Wang S, Wang L, Li Y: Glandular odontogenic cyst in China: report of 12 cases and immunohistochemical study. *J Oral Pathol Med* 35:175e182, 2006.
- Krishnamurthy A, Sherlin HJ, Ramalingam K, Natesan A, Premkumar P, Ramani P, et al. Glandular odontogenic cyst: Report of two cases and review of literature. *Head Neck Pathol* 2009;3:153-8.
- Noffke C, Raubenheimer EJ. The glandular odontogenic cyst: clinical and Radiological features; review of literature and report of nine cases. *Dentomaxillofac Radiol.* 2002;31:333.
- Manor R, Anavi Y, Kaplan I, Calderon S. Radiological features of glandular odontogenic cyst. *Dentomaxillofac Radiol.* 2003;32:73-9.
- Hellstein J, Hopkins T, Morgan T. The history and mystery of Carnoy solution: an assessment of the need for chloroform. *Oral Surg Oral Med Oral Pathol Oral Radiol Endod.* 2007;103(4):524.
- Ophir Ribeiro Júnior, Alexandre Meireles Borba1, Carlos Augusto Ferreira Alves, Jayro Guimarães Júnior. Carnoy’s solution over the inferior alveolar nerve as a complementary treatment for keratocystic odontogenic tumors. *Rev. Clín. Pesq. Odontol.* 2007;3(3):199-202.
- Hécio Henrique Araújo de Moraes, Ricardo José de Holanda Vasconcellos, Thiago de Santana Santos, Lélia Maria Guedes Queiroz, Éricka Janine Dantas da Silveira. Glandular odontogenic cyst: case report and review of diagnostic criteria. *J Cranio-Maxillo-Facial Surg.* 2012;40:e46-e50.