

## Morphometric evaluation of styloid process on digital panoramic radiograph- an radioanthropometric study

Akhilanand Chaurasia<sup>1,\*</sup>, Amit Chaudhary<sup>2</sup>, Ranjitskumar Patil<sup>3</sup>

<sup>1</sup>Assistant Professor, <sup>2</sup>Resident, <sup>3</sup>Professor, Dept. of Oral Medicine & Radiology, Faculty of Dental Sciences, King George's Medical University, Lucknow, Uttar Pradesh

**\*Corresponding Author:**

Email: chaurasiaakhilanand49@gmail.com

### Abstract

**Objective:** This research article aims at age and sex related changes in styloid process. This study also helps in determination of age and sex on the basis of length of styloid process.

**Materials and Method:** The orthopantomograms of 200 subjects were taken from planmeca promax-dimax4 OPG machine at 66 Kvp, 8mA and exposure time 16 sec. All the measurements are done on digital orthopantomograms using planmeca Romexis 3.2.0R software. The measurements of the styloid process will be subjected to discriminant function analysis.

**Results:** The study samples consists of 200 study subjects aged between 9 and 77 years with a mean age of 39.11±16.648 years. The t test showed no significance ( $p>0.05$ ) in the length of styloid process in either side of male and female. The one way ANOVA test showed that length of right styloid process is statistically significant ( $p<0.05$ ) and slightly higher in 36 to 50 years of age group. However, length of Left styloid process were not differed ( $p>0.05$ ) between the age groups i.e. found to be statistically the same. The Pearson correlation coefficient ( $r$ ) shows no obvious significant correlation between age of study subjects with length of left styloid process however length of right styloid process were directly associated with age and demonstrate a significant positive relation.

**Conclusion:** Dentists should recognize the existence of morphological variation in calcified stylohyoid complexes, especially in length apparent on panoramic radiographs. The present research paper concludes that the length of styloid process can be used as morphometric tool in determination of age and sex of a particular individual having gender identification and age issues.

**Keywords:** Styloid process, Forensic odontology, Panoramic Radiograph

### Introduction

The age and sex estimation is one of the most important steps in identification of the biological profile of the dismembered and skeletal remains. The accuracy of skeletal sex estimation relies on the sexual dimorphism exhibited by the human body. From previous studies, the pelvis and skull have been considered the most reliable for identification of the sex of unknown remains.<sup>(1)</sup> Additionally, studies on the sex estimation have been conducted on various skeletal elements such as the scapula, sternum, clavicle, patella, hand and foot bones.<sup>(2,3,4)</sup> However no studies have been focused on the sex estimation using the styloid process.

The word styloid process has been originated from the word 'stylos,' which means, the pillar, in Greek language.<sup>(5)</sup> This process belongs to the temporal bone of the skull and it lies anterior to the stylomastoid foramen. Being cylindrical in shape, the styloid process gradually tapers towards the apex just like a pinnacle. Its apex is located next to the tonsillar area in the lateral wall of pharynx, between external and internal carotid arteries. Its tip provides attachment to the stylohyoid ligament. There are few structures blended to the stylos process, which are in relation to the nerves and vessels. The stylopharyngeus, stylohyoid and styloglossus are the muscles which attach to the base, middle part and tip of the styloid process respectively. These muscles get the innervations from the 9th, 7th, and 12th cranial

nerves.<sup>(6)</sup> Spinal accessory and vagus nerves run medial to the styloid process. The facial nerve runs anteromedial to this process before piercing the substance of the parotid gland. Glossopharyngeal nerve curves in close proximity to the stylos process. The styloid process is a cylindrical bony projection extending from the petrous portion of the temporal bone. It lies in front of the stylomastoid foramen and projects downwards, forwards, and slightly towards the medial side. The location of the apex of the styloid process is clinically important, which is located between internal carotid and external carotid arteries, posterolateral to the tonsillar fossa and laterally from the pharyngeal wall. There are many structures surrounding the styloid process, such as the facial nerve crosses to the base and external carotid artery crosses its apex of this process before embedded in the parotid gland. In addition, three muscles and two ligaments are attached to the styloid process. Stylopharyngeus, stylohyoid and styloglossus muscles are attached to the base, middle part and tip of the styloid process, respectively. The stylohyoid and stylomandibular ligaments extend from the tip of the styloid process to the hyoid bone and the angle of mandible, respectively.<sup>(7)</sup>

Normal length of styloid process in adults can vary between 20 and 25 millimeters.<sup>(8)</sup> Styloid complex includes three chief sections; styloid tuberosity, styloid ligament, and little horn of hyoid bone.<sup>(9)</sup> Styloid

tubercosity is situated in the parapharyngeal cavity in the purlieu of vascular and neural constructions which could be motivated by lengthened or inappropriate styloid tubercosity and grounds several complications.<sup>(10)</sup> Calcification of the styloid tubercosity begins before birth and continues up to eight years of age.<sup>(10)</sup> The length of this tubercosity varies significantly in various populations and also differs among people of the same population.<sup>(10,11,12)</sup> Furthermore, the normal length of the tubercosity seems to be in the range from 20 to 30 mm,<sup>(13,14,15)</sup> while there are also studies that described this range as between 20-25 mm.<sup>(14)</sup> However Eagle has outlined that the normal length of styloid tubercosity is in a range from 25 to 30 mm.<sup>(10)</sup> In the cases that the length of the tubercosity is higher than 30 mm, it is called an elongated tubercosity.<sup>(13,11)</sup> Some studies have reported that almost four percent of world population is suffering from an elongated styloid tubercosity.<sup>(12,16)</sup> Nevertheless, some studies have explained that the prevalence of this type of styloid tubercosity is as high as 28 percent.<sup>(13)</sup> In addition, it is observed that the prevalence of elongated styloid tubercosity is higher on the right side in comparison to its prevalence in the left side which can be attributed to a higher activity of the right hemi mandible in right-hand people during chewing.<sup>(10)</sup>

Styloid processes longer than 30mm are called elongated styloid processes (ESP).<sup>(17,18,19)</sup> Incidence of elongation of styloid process is around 4–7%; only 4% of patients with elongation of styloid process show the symptoms.<sup>(17,20)</sup> In the event that elongation of styloid process causes clinical symptoms like neck and cervicofacial pain, it is described as Eagle syndrome.<sup>(18,21)</sup> This sign and symptom are believed to be formed due to styloid process pressure on some nerve and vascular structures situated around the styloid process like facial nerve or internal or external carotid arteries. More occasionally, dysphagia, tinnitus, and otalgia can occur in Eagle syndrome.

## Materials and Method

The orthopantomograms of 200 subjects were taken from planmeca promax-dimax4 OPG machine at 66 Kvp, 8mA and exposure time 16 sec. All the measurements are done on digital orthopantomograms using planmeca Romexis 3.2.0R software. The subject was positioned properly in the panoramic machine set up so that the jaws were within the focal trough as per the methodology described by Langland, Langlais and Morris (1982). The subject was made to stand erect with back straight. The height was adjusted by pressing the adjustable knob. The subjects were explained about the working of the machine. The operation of the panoramic machine was demonstrated to the subjects and the subjects were appraised of the need to be still during the procedure. Jacket, sweater and bulky dress materials were removed so that there could be sufficient space between the bottom of the cassette holder and

patients shoulder. The subject was made to wear a lead apron and was positioned carefully in the focal trough with the help of bite block covered with occlusal disposable envelope and head holder of the machine so that the lower border of mandible was equidistant on each side from the chin support and perpendicular to the Frankfurt horizontal plane. Frankfurt horizontal plane was maintained parallel to the floor of the clinic. The patient's midsagittal plane was positioned in the center of the focal trough of the x-ray unit by asking the patient to bite with his central incisors (upper and lower). The patient was asked to close the lip and place the tongue against the palate. Automatic exposure parameters were selected. After all the adjustments were made, appropriate 66 Kvp and 8mA were selected and exposure were made at 16 sec of exposure time by depressing the control switch of the panoramic machine. The orthopantomogram is displayed on console computer. The image is saved and stored in computer. Then image of orthopantomogram is opened with inbuilt planmeca Romexis 3.2.0R software for measurement of study parameters. The study parameters are measured using mouse-driven method by moving the mouse and drawing lines using chosen points on the digital panoramic radiograph as follows(Fig. 1). From base of styloid process to tip of styloid process.

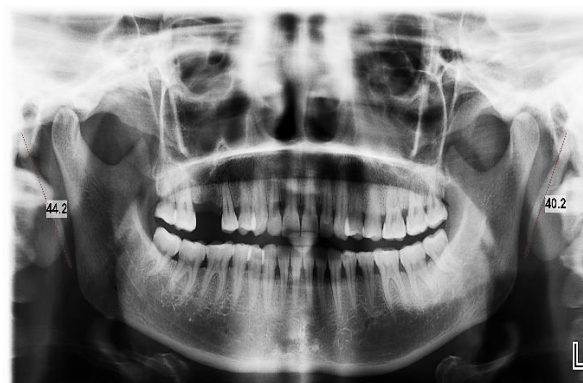

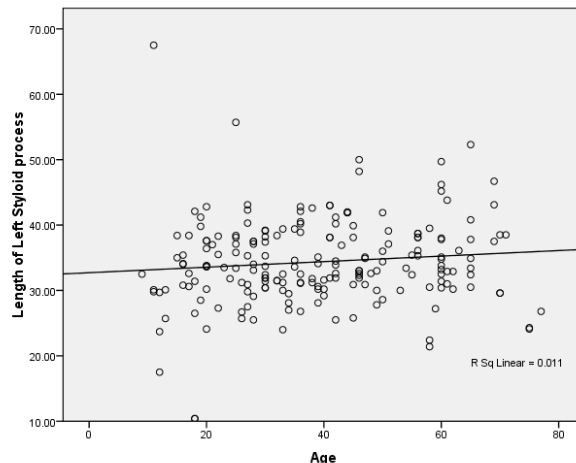
Fig. 1

**Statistical Analysis:** Categorical variables will be presented in number and percentage (%) and continuous variables will be presented as mean and SD. Quantitative variables will be compared using Unpaired t-test between two groups and ANOVA between three groups. The data were analyzed by the discriminant function analysis using Fischer exact test. Pearson correlation coefficients were used to determine the relationship between two scale parameters. A p value of <0.05 will be considered statistically significant. The data will be entered in MS EXCEL spreadsheet and analysis will be done using Statistical Package for Social Sciences (SPSS) version 21.0.

**Results**

The study samples consists of 200 study subjects aged between 9 and 77 years with a mean age of 39.11±16.648 years (Table 1). Majority of the study subjects were between 18 to 35 years of age(Table 2). The sex ratio in our study population showed that male proportion was higher than female i.e. 55.5% and 44.5% respectively (Table 3). Unpaired t test is applied to know the significance of styloid length (right and left) in relation to sex of study population. The t test showed no significance (p>0.05) in males and females i.e. the length of styloid process in either side is statically not significant in either sex(Table 4).

The one way ANOVA test is used to know the level of significance between lengths of styloid process in age groups. It showed that length of right styloid process is statistically significant(p<0.05) and slightly higher in 36 to 50 years of age group. However, length of Left styloid process were not differed (p>0.05) between the age groups i.e. found to be statistically the same(Table 5). Table 6 shows Pearson correlation coefficient (r), significance value and their linear equation. There was no obvious significant correlation between age of study subjects with length of left styloid process however length of right styloid process were directly associated with age and demonstrate a significant positive relation (r=0.188, p=0.008). The mathematical; equations derived from linear regression analysis can be used for prediction of age of study subjects if length of the styloid process of either side is known(Graph 1 & 2).



Age =22.396+.489\*(Length of right styloid process)  
 Age =30.082+.263\*(Length of Left styloid process)

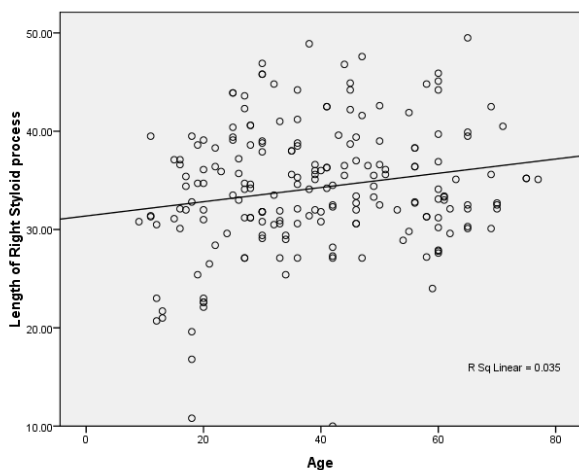
Table 6 shows the mean comparison of parameters according to their gender using discriminant function analysis using Fisher exact test. Higher mean were observed in length of Right styloid process and length of Left styloid process of males in comparison to females. Statistically no significant difference were observed in length of right styloid process and length of left styloid process (P>0.05) in both sex. The sex of a study subject can be determined from calculations using the equations given below.

**D of Male:** -19.013+ .566 (Length of Right styloid process) + .485 (Length of left styloid process)

**D of Females:** -17.697+ .552 (Length of right styloid process) + .461 (Length of left styloid process)

Sex was accurately determined in 99 cases out of 111 male measurements with prediction accuracy rate of 89.2% and sex was accurately determined in 14 cases out of 89 female measurements with an accuracy rate of 15.7%(Table 8).

**Graph 1**



**Graph 2**

**Table 1**

	N	Minimum	Maximum	Mean	Std. Deviation
Age	200	9	77	39.11	16.648

**Table 2**

Gender	Frequency	Percent
Male	111	55.5
Female	89	44.5
Total	200	100.0

**Table 3**

Age intervals	Frequency	Percent
Below 18 years	23	11.5
18 to 35 years	67	33.5
36 to 50 years	58	29.0
51 to 65 years	42	21.0
More than 65 years	10	5.0
Total	200	100.0

**Table 4**

	Gender	N	Mean	Std. Deviation	P value
Length of Right styloid process	Male	111	34.7261	6.05351	0.207
	Female	89	33.5742	6.80706	
Length of left styloid process	Male	111	35.0027	6.02833	0.135
	Female	89	33.5809	7.37466	

Applied unpaired t test for significant.

**Table 5**

		N	Mean	Std. Deviation	P value
Length of Right styloid process	Below 18 years	23	29.3609	7.75311	0.002*
	18 to 35 years	67	34.3104	6.11754	
	36 to 50 years	58	35.6069	6.26034	
	51 to 65 years	42	34.5690	5.73413	
	More than 65 years	10	35.1500	3.81058	
Length of Left styloid process	Below 18 years	23	31.1609	11.20242	0.112
	18 to 35 years	67	34.1761	5.37703	
	36 to 50 years	58	35.1431	5.56108	
	51 to 65 years	42	35.4881	6.13472	
	More than 65 years	10	33.8700	8.02317	

Applied one way ANOVA for significance. \*significant

**Table 6**

	Pearson correlation coefficients (r)	P value	Equation linear
Length of right styloid process	.188**	.008	Age =22.396+.489*(Length of Right Styloid process)
Length of left styloid process	.105	.137	Age =30.082+.263*(Length of Left Styloid process)

\*\* Correlation is significant at the 0.05 level (2-tailed)

**Table 7**

	Male		Female		F value	P value
	Mean	Std. Deviation	Mean	Std. Deviation		
Length of Right Styloid process	34.7261	6.05351	33.5742	6.80706	1.601	0.207
Length of Left Styloid process	35.0027	6.02833	33.5809	7.37466	2.251	0.135

**Table 8**

		Gender	Predicted Group Membership		Total
			Male	Female	
Original	Count	Male	99	12	111
		Female	75	14	89
	%	Male	89.2	10.8	100.0
		Female	84.3	15.7	100.0
56.5% of original grouped cases correctly classified.					

## Discussion

Krogman and Iscan et al<sup>(1)</sup> stated that the identification of the sex of skeletal remains is important in the execution of the forensic anthropological examination. For this purpose, the information on

sexual dimorphism of human skeleton is useful in terms of the morphology differences as well as the larger size of male. They further stated that the sex identification with 100% accuracy is possible when the whole skeleton is utilized, while the 98% accuracy is possible

by using the pelvis and the skull, the 95% accuracy by the pelvis alone, and 92% by the skull alone. Furthermore, there have been studies to estimate the value for sex identification of various parts of the skeleton such as patella, mastoid process, scapula and clavicle, and first rib.<sup>(22,23)</sup> However, no estimation of the value has so far been done about the styloid process.

RD Murtagh et al<sup>(24)</sup> and JS Rechtweg et al<sup>(25)</sup> stated that the dimension of styloid process usually varies, ranging up to 25 mm. The elongated styloid process can be clinically detected by palpating the tonsillar fossa and is diagnosed by taking the X-ray lateral view of the neck, orthopantomogram (OPG) or a computerized axial tomogram (CT). Although there is no gender predilection for the elongated styloid process, the symptoms tend to be more common in the middle aged females.

The length of styloid process of temporal bone varies from population to population. Eagle et al<sup>(26)</sup> reported that a normal styloid process measures between 25 mm to 30 mm and any length more than the above mentioned values, is considered as the pathogenic factor for Eagle syndrome. Keur et al<sup>(6)</sup> suggested that the styloid process length and its mineralized stylohyoid ligament, if appears more than 30 mm in a radiograph film, is considered as a significant predisposing factor. However, Jung et al<sup>(27)</sup> suggested that, a styloid process of only more than 45 mm length should be considered to be elongated.

R Vadgaonkar et al<sup>(28)</sup> observed that the mean length of the styloid process was  $17.8 \pm 9.3$  mm and  $18.2 \pm 5.6$  mm for the right and left sides, respectively. This data is smaller in comparison to the data from North Indian population reported by Rathva et al.<sup>(29)</sup> Rathva et al<sup>(29)</sup> reported that the length of styloid process was  $43.8 \pm 11.1$  mm and  $43.5 \pm 10.4$  mm for the right and left sides in their specimens. This variation in the data from Indian samples may be because the difference in the method which was used to measure the parameter as they performed the measurements by using digital image analysis using the adobe photoshop.

Patil et al<sup>(30)</sup> stated that the mean of distance between the bases of two styloid process was  $69 \pm 5.2$  mm and the same parameter between the tips of two styloid processes was  $64 \pm 6.1$  mm. Hussain et al<sup>(31)</sup> have reported that its length in male is larger than that in female at both right and left sides with a statistically significance.

Thot et al<sup>(32)</sup> have reported that left styloid process length is between 0.7 and 1.6 centimeters and right styloid process length is between 0.8 and 2.4 centimeters.

Where as in our study on comparing the mean of clinical characteristics of two groups (Males and Females), t test showed not differed ( $p > 0.05$ ) between the two groups (Males and Females) i.e. found to be statistically the same and also on comparing the mean of clinical characteristics of age groups, t test showed

significantly ( $p < 0.05$ ) different and slightly higher in 36 to 50 years of age group. However, Length of Left Styloid process were not differed ( $p > 0.05$ ) between the Age groups i.e. found to be statistically the same.

We observed that there was no obvious significant correlation between age of patients with Length of Left Styloid process. While Length of Right Styloid process were directly associated with Age and demonstrate a significant positive relation ( $r = 0.188$ ,  $p = 0.008$ ).

On comparing the parameters according to their gender using discriminant function analysis using Fisher exact test. It's shows that higher mean were observed in Length of Right Styloid process and Length of Left Styloid process of Males compare to females. Statistically no significant difference were observed in Length of Right Styloid process and Length of Left Styloid process ( $P > 0.05$ ).

The results of this study indicated that the styloid process has a good potential for sex identification. The knowledge length of the styloid process and prevalence of the elongated styloid process are important and useful to the anatomists, anthropologists, radiologists, and clinicians.

## References

1. Krogman, W. M. & Iscan, M. Y. The Human Skeleton in Forensic Medicine. 2nd ed. Springfield, Charles C. Thomas Publisher, 1986.
2. Singh, J.; Pathak, R. K. & Singh, D. Morphometric sex determination from various sternal widths of Northwest Indian sternums collected from autopsy cadavers: A comparison of sexing methods. Egypt. J. Forensic Sci., 2(1):18-28, 2012.
3. Smith, S. L. Attribution of hand bones to sex and population groups. J. Forensic Sci., 41(3):469-77, 1996.
4. Viwatpinyo, K.; Case, D. T. & Mahakkanukrauh, P. Sex estimation from the navicular bone in a Thai population. Siriraj Med. J., 66(6):210-8, 2014.
5. Magotra R, Razdan S. Elongated styloid process: anatomical variations. JK Sci. 2008;10:203-205.
6. Keur JJ, Campbell JP, McCarthy JF, Ralph WJ. The clinical significance of the elongated styloid process. Oral Surg Oral Med Oral Pathol. 1986;61:399-404.
7. Standring, S. Gray's Anatomy. The Anatomical Basis of Clinical Practice. 40th ed. Edingburgh, Churchill Livingstone/Elsevier, 2008.
8. W. W. Eagle, "Elongated styloid process; further observations and a new syndrome," Archives of Otolaryngology, vol. 47, no. 5, pp. 630-640, 1948.
9. Fini G, Gasparini G, Filippini F, Becelli R, Marcotullio D. The long styloid process syndrome or Eagle's syndrome. Journal of cranio-maxillofacial surgery. 2000;28(2):123-7.
10. Natsis K, Repousi E, Noussios G, Papatheanasiou E, Apostolidis S, Piagkou M. The styloid process in a Greek population: an anatomical study with clinical implications. Anatomical science international. 2015;90(2):67-74.
11. Besir FH, Yaman H, Erdogmus B. Comment on "Is there a relationship between symptoms of patients and tomographic characteristics of styloid process?" (Okur et al. Surg Radiol Anat doi: 10.1007/s00276-013-1213-2). Surgical and Radiologic Anatomy. 2014;36(9):951-2.

12. Okabe S, Morimoto Y, Ansai T, Yamada K, Tanaka T, Awano S, et al. Clinical significance and variation of the advanced calcified stylohyoid complex detected by panoramic radiographs among 80-year-old subjects. *Dentomaxillofacial Radiology*. 2014.
13. Singla RK, Shree B, Sharma RK. Bilaterally Elongated Styloid Process—A Case Report. *image*.25:28mm.
14. Fini G, Gasparini G, Filippini F, Becelli R, Marcotullio D. The long styloid process syndrome or Eagle's syndrome. *Journal of cranio-maxillofacial surgery*. 2000;28(2):123-7.
15. Kumar U. Unusual Bilateral Elongation of Styloid Process in a Human Dry Skull: A Case Report. *International Journal of Health Sciences and Research (IJHSR)*. 2014;4(6):212-5.
16. Alpoz E, Akar GC, Celik S, Govsa F, Lomcali G. Prevalence and pattern of stylohyoid chain complex patterns detected by panoramic radiographs among Turkish population. *Surgical and Radiologic Anatomy*. 2014;36(1):39-46.
17. K. C. Prasad, M. P. Kamath, K. J. M. Reddy, K. Raju, and S. Agarwal, "Elongated styloid process (Eagle's syndrome): a clinical study," *Journal of Oral and Maxillofacial Surgery*, vol. 60, no. 2, pp. 171–175, 2002.
18. M. Ilgüy, D. Ilgüy, N. Güler, and G. Bayirli, "Incidence of the type and calcification patterns in patients with elongated styloid process," *Journal of International Medical Research*, vol. 33, no. 1, pp. 96–102, 2005.
19. T. Jung, H. Tschernitschek, H. Hippen, B. Schneider, and L. Borchers, "Elongated styloid process: when is it really elongated?" *Dentomaxillofacial Radiology*, vol. 33, no. 2, pp. 119–124, 2004.
20. V. Chourdia, "Elongated styloid process (Eagle's syndrome) & severe headache," *Indian Journal of Otolaryngology and Head and Neck Surgery*, vol. 54, no. 3, pp. 238–241, 2002.
21. P. Kursoglu, F. Unalan, and T. Erdem, "Radiological evaluation of the styloid process in young adults resident in Turkey's Yeditepe University faculty of dentistry," *Oral Surgery, Oral Medicine, Oral Pathology, Oral Radiology and Endodontology*, vol. 100, no. 4, pp. 491–494, 2005.
22. Introna, F. Jr.; Di Vella, G. & Campobasso, C. P. Sex determination by discriminant analysis of patella measurements. *Forensic Sci. Int.*,95(1):39-45, 1998.
23. Kubicka, A. M. & Piontek, J. Sex estimation from measurements of the first rib in a contemporary Polish population. *Int. J. Legal Med.*, 130(1):265-72, 2016.
24. Murtagh RD, Caracciolo JT, Fernandez G. CT findings associated with Eagle syndrome. *AJNR Am J Neuroradiol*. 2001;22:1401–1402.
25. Rechtweg JS, Wax MK. Eagle's syndrome: a review. *Am J Otolaryngol*. 1998;19:316–321.
26. Eagle WW. The symptoms, diagnosis and treatment of the elongated styloid process. *Am Surg*. 1962;28:1–5.
27. Jung T, Tschernitschek H, Hippen H, Schneider B, Borchers L. Elongated styloid process: when is it really elongated? *Dentomaxillofac Radiol*. 2004;33:119–124.
28. Rajanigandha Vadgaonkar, B. V. Murlimanju, Latha V. Prabhu, Rajalakshmi Rai, Mangala M. Pai, Mamatha Tonse, P. J. Jiji Morphological study of styloid process of the temporal bone and its clinical implications *Anat Cell Biol*. 2015 Sep;48(3):195–200.
29. Rathva A, Kubavat DM, Nagar SK. Study of styloid process: anatomical variations in length, angulation and distance between the two styloid processes. *Int J Recent Trends Sci Technol*. 2013;8:109–112.
30. Patil S, Ghosh S, Vasudeva N. Morphometric study of the styloid process of temporal bone. *J Clin Diagn Res*. 2014;8:AC04–AC06.
31. Hussain, S. S.; Muralidhar, P. S. & Haseena, S. Study the length of styloid process in South Indian adults dry skulls. *J. Pharm.Sci. Res.*,3(9):1456-9, 2011
32. B. Thot, S. Revel, R. Mohandas, A. V. Rao, and A. Kumar, "Eagle' syndrome. Anatomy of the styloid process," *Indian Journal of Dental Research*, vol. 11, no. 2, pp. 65–70, 2000.