

Validity of Orthopantomograph, Cone Beam Computed Tomography and CT for assessment of simulated lesions over mandibular condyle

Vinuta Hegde^{1,*}, Venkatesh G. Naikmasur², Krishna N. Burde³, Gautam R. Jayade⁴

¹Junior Resident, Dept. of Dentistry, Karwar Institute of Medical Sciences, Karwar, Karnataka, ²Professor, ³Professor & HOD, Dept. of Oral Medicine & Radiology, ⁴Reader, Dept. of Oral & Maxillofacial Surgery, SDM College of Dental Sciences & Hospital, Dharwad, Karnataka

***Corresponding Author:**

Email: drvinu07@yahoo.co.in

Abstract

Objectives: Purpose of present study was to assess the validity of Orthopantomograph (OPG), limited volume Cone Beam Computed Tomography (CBCT) and Computed Tomography (CT) in evaluating the simulated lesions over the mandibular condyles.

Materials and Method: 15 dry human mandibles (30 mandibular condyles) with intact mandibular condyles were used in this study. Total of 46 lesions were created randomly on anterosuperior (AS), superior (S) and posterosuperior (PS) surfaces of the condyle with 1mm surgical bur. Subsequently all the mandibles were subjected to OPG, CBCT and CT for assessing artificially created lesions. Two observers assessed the images for presence or absence of the lesions, number and surface of the lesions in each condyle.

Results: Statistically good agreement was obtained between 2 observers in assessment of the lesions with all the three imaging modalities. With CBCT 100% sensitivity and specificity was obtained. CT produced 96.67% sensitivity and 100% specificity. Sensitivity obtained with OPG was 24.14% and specificity was 100%. Good agreement was obtained between CT and CBCT in detecting the lesions and it was found to be 96.67%.

Conclusion: Accuracy of CBCT was found to be 100% and it was superior to CT (96.67%) in detecting the lesions over the mandibular condyle and OPG produced least accuracy (24.14%). Owing to the facts like high radiation dose and high cost of CT, we suggest CBCT as a better imaging modality for incipient bony changes of TMJ. However further studies with more samples are required to confirm these results.

Keywords: TMJ; Simulated lesions; OPG; CT; CBCT.

Introduction

Temporomandibular joint disorders (TMD) include a heterogeneous group of pathologies affecting the articular disk and associated ligaments and muscles, growth or developmental abnormalities, joint arthritides and neoplasms. It is the most common jaw disorder, with 28% to 86% of adults and adolescents showing one or more clinical signs or symptoms.^(1,2) The TMJ can suffer modifications caused by internal degeneration, fractures, neoplasms and inflammatory processes.⁽³⁾ TMDs are frequently associated with degenerative bony changes of the TMJ such as flattening, erosion, osteophytes, subchondral bone sclerosis and pseudocysts.⁽⁴⁾ Osseous changes of TMJ have been radiographically observed in 14 - 44% of TMD patients using two-dimensional imaging.⁽⁵⁾ More accurate diagnosis is critical for understanding the pathophysiology and designing treatment plans for these TMJ diseases.

Panoramic radiography (Orthopantomography), conventional linear or complex motion tomography and CT are most commonly used to assess the osseous components of the joints, whereas magnetic resonance imaging (MRI) is used to assess the soft tissue components.^(6,7) Panoramic projection serves as a screening projection to identify odontogenic diseases and other disorders that may be the source of TMJ symptoms and in evaluating gross TMJ osseous

pathology.⁽¹⁾ Although Orthopantomography is simple and relatively inexpensive, these radiographs do not show the entire articular surfaces of the TMJ, structures here are distorted and often there is superimposition from the zygomatic process. These radiographs have a poor reliability and low sensitivity for detecting TMJ osseous changes.^(8,9)

CT provides excellent visualization of broad spectrum of osseous pathological changes. Studies on autopsy specimens found CT to have a sensitivity of 75% and a specificity of 100% for detecting bony changes.⁽¹⁰⁾ However the high cost, difficult access to the equipment and relatively high radiation dose have limited widespread use of CT for TMJ evaluation.

Cone Beam Computed Tomography (CBCT) also called as digital volume tomography (DVT) is a recent technology which provides high definition three dimensional (3D) digital data on precise anatomical location of all oral and maxillofacial structures. In addition to the lower cost and better access to equipment, CBCT offers several advantages over medical CT like lower radiation dose and higher spatial resolution and it also allows for 3D reconstruction of the image. The diagnostic efficacy of CBCT is as good as conventional CT and is superior to that of panoramic radiography and linear tomography.⁽¹¹⁻¹³⁾

TMJ imaging is very challenging because the bony components are small and superimpositions from the base of the skull often result in a lack of clear delineation of the joint. Each TMJ imaging modality has its own advantages and disadvantages. Practically it is not viable to assess condylar changes in patients with TMD with multiple imaging modalities owing to the high radiation exposure, time and high imaging costs. Present study aimed to assess the validity of OPG, CBCT and CT in evaluating the simulated lesions over the mandibular condyles.

Materials and Method

This was a blinded observational, in-vitro study which was conducted after obtaining the Ethical and Institutional Board clearance. A total of 15 dry human mandibles (30 mandibular condyles) were used in this study. No demographic data were available on them; they were not identified by age, sex or ethnicity. Anatomical specimens of human mandible with intact mandibular condyles bilaterally were included and mandibular specimens with severed condyles were excluded from the study.

Each mandibular condyle was divided into three surfaces: anterosuperior (AS), superior (S) and posterosuperior (PS). Using a NSK high-speed hand piece (NSK EX6, Made in Japan) and a carbide bur with 1mm head diameter (MANI Carbide burs, Prime Dental Products PVT LTD), lesions were made randomly in one or more above mentioned surfaces of condyles to simulate bone lesions. Individual lesions were created till it reached the medullary bone. Subsequently all the mandibles were subjected to three imaging modalities i.e. OPG, CBCT and CT for assessing artificially created lesions.

KODAK 9000C 3D Extraoral imaging system (Care stream Health, Inc. 150 Verona Street Rochester New York - USA 14608) was used for obtaining OPG and DVT images. SOMATOM Definition AS (SIEMENS AG, Wittelsbacherplatz 2, DE – 80333, Muenchen, Germany) was utilized for CT imaging. The mandible was positioned in the machine by using a custom made thermocol base for all three imaging methods that was representative of an average mandibular position in the machine. The symphyseal region of the each mandible was positioned in the chin holder of imaging system both for OPG and CBCT. Vertical and horizontal laser reference beams were utilized to position the mandible.

KODAK 9000C 3D Extraoral imaging system with a reconstruction volume of 50x37mm and a reconstructed matrix voxel of 76.5x76.5x76.5µm was used to obtain the CBCT images. As the field of view was small i.e. 50x37mm, two CBCT images were taken for each mandible, one for each condyle. The equipment

has Complementary metal-oxide-semiconductor (CMOS) sensor technology with a gray scale of 16384 – 14 bits. Condyles were assessed by the 3D volumetric image and 76µm tomographic sections in sagittal, axial and coronal planes.

CT scans were obtained with a Multislice (128 slice) helical CT machine using helical (spiral) scanning mode with 0.55 pitch in bony window settings. The mandibles were scanned in the normal anatomical position of the mandible (supine position). Laser beams were adjusted for the axial and midsagittal planes. Axial slices of 0.6mm were obtained from the ascending ramus to 2mm above the head of the condyle. Multiplanar reconstructed images of coronal and sagittal sections and 3D reconstruction were derived from axial sections using Syngo software (Siemens) on a personal computer. They were performed with Recon matrix of 512x512 pixel size with 0.6mm slice thickness and 0.6mm image interval. The CT images were then copied to a compact disc and labeled with its unique code same as that of OPG and CBCT. In CBCT and CT minimum slice thickness available in the respective machines were chosen for imaging the condyles. Hence slice thickness in CBCT and CT were 0.076mm and 0.6mm respectively.

Each condylar head was assessed for presence or absence of the lesions and number of lesions on above mentioned surfaces in each imaging modalities. The assessment was done by two observers who were blinded to each other as well as to lesions on each condyle. Both observers independently assessed all three imaging modalities for osseous defects. Observers were allowed to scroll through the images in all three planes, i.e. axial, coronal and sagittal and also to view 3D reconstructed images.

Statistical Analysis: Obtained data were subjected to statistical analysis and compared with the gold standard. Sensitivity, specificity and validity tests were used to compare the accuracy of different imaging modalities in detecting condylar lesions. Kappa statistics was used to evaluate the agreement among the imaging modalities and interobserver variations.

Results

Total of 46 lesions were created on above mentioned surfaces of right and left condyles (Fig. 1). Table 1 shows the number of lesions and surfaces on which the lesions were created (gold standard). On applying Kappa statistics good agreement was obtained between 2 observers in assessment of the lesions with all the three imaging modalities (Table 2).

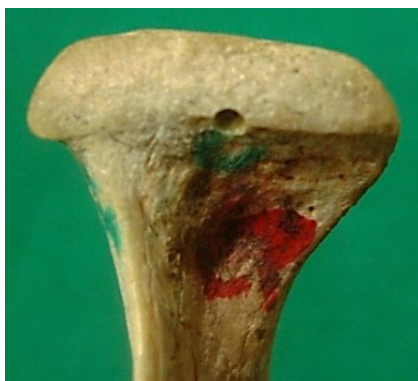

Fig. 1: Artificially created lesion on anterosuperior surface of right mandibular condyle (gold standard)

Table 1: Number of lesions on different surfaces of the condyle (gold standard)

Surface of the condyle	Number of lesions
Anterosuperior	22
Superior	14
Posterosuperior	10
Total	46

Table 2: Interobserver agreement in different imaging modalities

Imaging modality	Percentage of agreement	Kappa value	Standard error	Z- value	P-value
OPG	80.00%	0.37	0.17	2.12	0.0169*
CT	92.22%	0.61	0.14	4.25	0.00001*
CBCT	100.00%	1.00	0.14	6.72	0.00001*

*p<0.05

OPG-orthopantomograph, CT-computed tomography, CBCT- cone beam computed tomography

With CBCT all 46 lesions and with CT 44 lesions out of 46 were correctly identified when compared to gold standard. However only 7 lesions were correctly identified with OPG. Average percentage of agreement, in relation to the gold standard in saying presence or absence of lesions with CBCT, CT and OPG when considered all regions of the condyles were 100%, 96.67% and 31.81% respectively (Table 3).

Table 3: Average comparison of agreements in detecting the number of lesions when compared to the gold standard

Imaging modality	Percentage of agreement	Kappa value	Standard error	Z- value	p-value
OPG	31.81 %	0.0118	0.0211	0.5600	0.2874
CT	96.67%	0.8421	0.1462	5.7600	0.00001*
CBCT	100.00%	1.0000	0.1487	6.7200	0.00001*

*p<0.05

CBCT produced 100% sensitivity and specificity. Sensitivity obtained was least with OPG i.e. 24.14% however specificity was 100%. CT produced 96.67% and 100% of sensitivity and specificity respectively. Validity (accuracy) which was given by Youden’s *J* index (sensitivity + specificity - 100) was also calculated for each modality (Table 4). Good agreement (Table 5) was obtained between CT and CBCT in detecting the lesions and it was found to be 96.67% (p-value = 0.00001*).

Table 4: Accuracy of different imaging modalities in identification of simulated lesions over the mandibular condyle

Accuracy	OPG	CT	CBCT
Sensitivity %	24.14	96.67	100
Specificity %	100	100	100
Validity %	24.14	96.67	100

Table 5: Agreement among three imaging modalities in detecting the number of lesions

	OPG vs CT	OPG vs CBCT	CBCT vs CT
Agreement	60.00%	60.00%	96.67%
Kappa value	0.0128	0.0128	0.8421
Standard error	0.0228	0.0228	0.1462
Z value	0.5600	0.5600	5.7600

When compared to gold standard with CBCT all the lesions on all three surfaces were accurately identified by both the observers. With CT four lesions on the superior surface and two lesions on the posterosuperior surface were not identified by the first observer. Observer 2 did not identify two lesions on the superior surface of the condyle with CT images. Only five lesions by the first observer and seven by the second observer were identified on the anterosuperior surface with OPG but none on the superior and posterosuperior surfaces (Fig. 2 - 4). Hence in accordance with the surface involved CBCT produced 100% sensitivity and specificity in detecting the lesions. With CT for anterosuperior and posterosuperior surface sensitivity and specificity were 100%, for superior surface sensitivity was 87.5%, however specificity was again 100%. With OPG 59.45% sensitivity was obtained for anterosuperior surface.

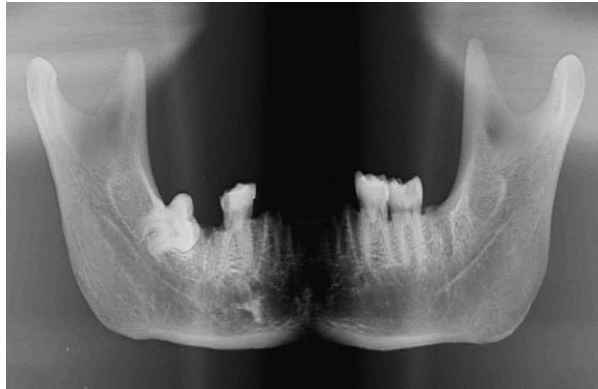


Fig. 2: OPG of the same mandible – lesion is not detected on the right condyle

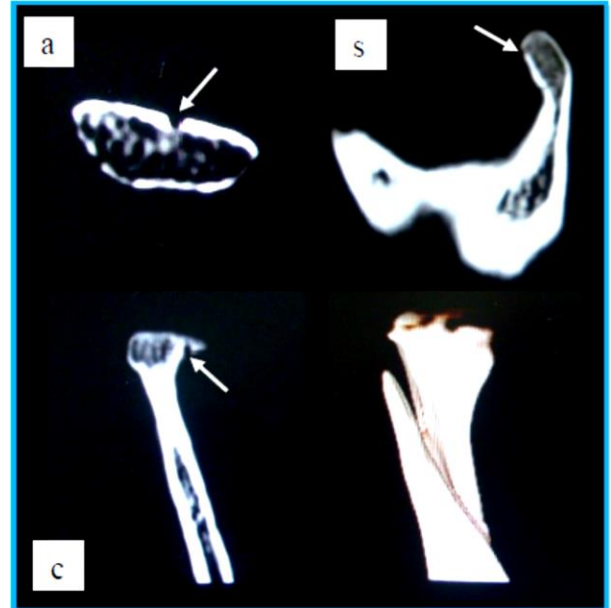


Fig. 3: Cropped CT images of the same condyle demonstrating the lesion on anterosuperior surface in axial (a), coronal (c) and sagittal (s) sections (arrows)

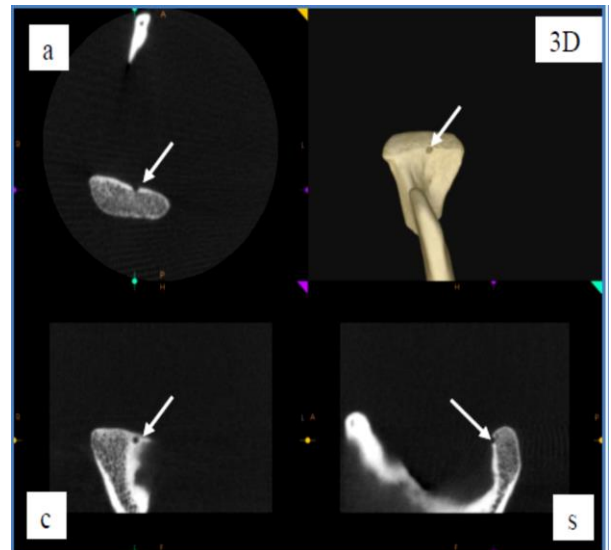


Fig. 4: CBCT images of the same condyle demonstrating the lesion on anterosuperior surface in axial (a), coronal (c), sagittal (s) sections and 3D reconstruction (arrows)

Discussion

Radiography is an important adjunct to clinical examination that can suggest presence or absence of bony pathology.^(14,15) Thus, a combination of clinical and radiographic examinations of the TMJ is important for detection of TMJ disorders.^(14,16) Staging osseous changes associated with degenerative joint disease of the TMJ is potentially helpful in diagnosis of disease progression.⁽¹⁷⁾ The goal of radiographic examination is to obtain the necessary diagnostic information without

unnecessary expense or radiation exposure to the patient. Hence most appropriate imaging modalities which provide new information that will influence patient care should be chosen.

The present study was aimed at comparing OPG, MDCT and CBCT for detecting the artificially created lesions over the mandibular condyle.

CT and CBCT produced higher accuracy than OPG. Low sensitivity of OPG (24.14%) could be because of the fact that it does not resolve minor alterations or defects in the jaw and the lesions were up to 1mm in diameter in the present study. Present study was similar to that of study by Masood et al regarding OPG findings of TMJ where four different sized pyramidal shaped bone chips were positioned at different aspects of the anterior surface of the condyle to simulate osteophytic changes. On the panoramic views even the largest chip size (2.0mm) was not well visualized. With digital-subtraction techniques, lesions at all locations were detected with greater accuracy ($P = 0.01$). Lesions located at the central and medial locations were detected with greater diagnostic accuracy with these imaging modalities than lesions at the lateral location in their study.⁽¹⁸⁾ Even in the present study all lesions detected in OPG were present in the center of anterosuperior surface of the condyle.

Honey OB et al⁽¹⁹⁾ compared the accuracy of CBCT with OPG and linear tomography in detection of cortical erosions affecting the mandibular condyle. They obtained significant differences between three modalities ($p = 0.024$) with CBCT being more accurate and they suggested that CBCT is more reliable than corrected angle linear tomography and OPG in the detection of condylar cortical erosion. Even we found very poor agreement between OPG and CBCT reading ($p = 0.2874$) in detecting the simulated lesions and CBCT produced 100% accuracy.

A comparison of digital OPG and CT was made in assessing rheumatoid arthritis of TMJ by Delantoni A et al.⁽²⁰⁾ Statistically significant differences were present between CT scans and OPG only for bony changes of the condylar head. In the present study though there was no superimposition of adjacent structures (we used only the dry mandible), we were not able to detect many of the erosive lesions on the condyle in OPG. It could be because the lesions that were present eccentrically (either towards lateral or medial pole of the condyle) were superimposed by the rest of the normal condyle. Similar to above mentioned studies many research studies have shown that OPG, have limited accuracy in the imaging of TMJ.^(7,21,22)

Higher accuracy of CBCT and CT was obtained in the present study in detecting the simulated lesions over the condyles. Results of our study are comparative to many previous studies. Cara ACB et al found the highest accuracy with axial-associated multiplanar reconstructed images of multislice CT in comparison to single slice CT.⁽²³⁾ They speculated that MDCT allows high image

quality from thinner slices (0.5mm) than with single-slice CT. This difference can be explained by the fact that the lesions with a depth of less than 1 mm were better detected with thinner slices. We used CT images of 0.6mm slice thickness to assess 1mm sized lesions and obtained better results (sensitivity - 97.17% and specificity - 100%) when compared to Cara et al's study (sensitivity - 93.1% and specificity -100%).

The diagnostic accuracy of CBCT and CT for detection of condylar bone defects over autopsy material were compared by Honda et al. They obtained 80% and 70% sensitivity with accuracy of 90% and 86% for CBCT and CT respectively in detecting the osseous changes. The specificity was 100% for both the techniques.⁽¹³⁾ Results of the present study were similar and in fact sensitivity and specificity of both CBCT (100%) and CT (96.67% and 100%) were higher.

Specificity of 85.48% - 88.71% for MDCT and 83.87% - 90.32% for CBCT was obtained with two observers in Zain-Alabdeen EH et al's study which was conducted to observe the surface osseous changes of the condylar head in four anatomical sites.⁽²⁴⁾ Good correlation was obtained between CT and CBCT. Our results are in concordance with the above mentioned study. Though the correlation between CT and CBCT was good in their study, the sensitivity rates with CT and CBCT were much less (50% for CT and 39% for CBCT) as compared to the present study (96.67% for CT and 100% for CBCT). It could be because of much thinner tomographic sections used in our study (CT - 0.6mm and CBCT - 76 μ m).

Similar slice thickness for CT (0.6mm) was used in a study which compared the accuracy of MDCT with CBCT in assessment of erosions of the condyle.⁽²⁵⁾ Agreement for CT (0.84) in present study was within the range of Shoostari's study (0.11 - 0.93). With CBCT very good agreement was obtained (1.0) when compared to gold standard. In their study sensitivity of CBCT was minimum at the lateral surface (27%) and maximum at the superior, posterior and anterior surfaces (100%). Also they found minimum specificity of CBCT for the medial and lateral surfaces (94%) and maximum for the superior, posterior and anterior surfaces (100%). In the present study sensitivity and specificity for all the surfaces were 100% in CBCT. In their study sensitivity of helical CT was minimum for the medial surface (22%) and maximum for the superior surface (88%), the specificity was minimum for the medial surface (88%) and maximum for the superior and posterior surfaces (100%). In the present study sensitivity of CT was minimum for superior surface (87.5%) and maximum for anterosuperior and posterosuperior surfaces (100%). However specificity was 100% for all the surfaces.

Present study was conducted under in-vitro conditions without soft tissue simulation and hence probably provided greater accuracy. But lower accuracy and specificity values are expected in the clinical setting where bones are surrounded by the soft tissue. However

both CT and CBCT are influenced by this factor. Also, using a bur for making lesions produces more well-defined border compared to those in clinical situation where the lesions are more diffuse. Hence this has to be considered while assessing the pathology in reality. One of the limitations of the present study was that we examined only the erosions without including other bony changes which appear on the radiographs. Another limitation was, the lesions were of similar size (1mm) on all the condyles. If we would have included lesions of different size, lesion size-specific sensitivity and specificity would have been calculated. Further research into this issue is recommended with a larger sample.

Even with high resolution imaging modalities like computed tomography, smaller the bone lesion, the more difficult is its identification.^(26,27) And in previous studies it was found that there was no significant difference in evaluation of erosions of condyle with CBCT and CT. Evidence also shows that CBCT with low exposure dose (compared to CT) and high resolution can provide high sensitivity, specificity and diagnostic accuracy for the assessment of condylar erosions compared to CT.⁽²⁵⁾ Few investigators suggested that CBCT should be used instead of CT because of radiation dose to which the patient is exposed is much lower. Furthermore, CBCT is superior to CT for visualizing bony changes in the TMJ, analysing lateral slices in isolation and combining coronal and lateral slices.^(19,27,28)

Conclusion

CT and CBCT produced higher accuracy than OPG in detecting the simulated lesions over the mandibular condyle. Accuracies of CT and CBCT were comparable and no statistical significant difference was obtained between these two modalities. However CBCT produced higher accuracy (100%) than CT (96.67%). As CBCT is significantly cheaper and it uses a considerably lower radiation dose than CT we suggest use of CBCT as a cost and dose-effective diagnostic imaging modality to detect osseous changes in temporomandibular disorders.

References

- White SC, Pharoah MJ. Oral Radiology - Principles and Interpretation. (6th edn). Noida, India: Elsevier, 2010.
- Greenberg MS, Glick M. Burket's Oral Medicine diagnosis and treatment. (9th edn). Ontario: BC Decker Inc, 2003.
- Kurita H, Ohtsuka A, Kobayashi H, Kurashina K. Resorption of the posterosuperior corner of the lateral part of the mandibular condyle correlates with progressive TMJ internal derangement. *Int J Oral Maxillofac Surg* 2003;32:363-367.
- Ahmed M, Hollender L, Anderson Q, Kartha K, Ohrbach R, Truelove, et al. Research diagnostic criteria for temporomandibular disorders (RDC/TMD): development of image analysis criteria and examiner reliability for image analysis. *Oral Surg Oral Med Oral Pathol Oral Radiol Endod* 2009;107:844-860.
- Carlsson GE, Sessle BJ, Zarb GA, Mohl ND: Temporomandibular joint and masticatory muscle disorders. 2nd ed. Munksgaard, Copenhagen;1994:159-170.
- Kononen M, Kilpinen E. Comparison of three radiographic methods in screening of temporomandibular joint involvement in patients with psoriatic arthritis. *Acta Odontol Scand* 1990;48:271-277.
- Brooks SL, Brand JW, Gibbs SJ, et al. Imaging of the temporomandibular joint: a position paper of the American Academy of Oral and Maxillofacial Radiology. *Oral Surg Oral Med Oral Pathol Oral Radiol Endod* 1997;83:609-618.
- Crow HC, Parks E, Campbell JH, Stucki DS, Daggy J. The utility of panoramic radiography in temporomandibular joint assessment. *Dentomaxillofac Radiol* 2005;34:91-95.
- Shintaku WH, Venturin JS, Azevedo B, Noujeim M. Applications of cone-beam computed tomography in fractures of the maxillofacial complex. *Dental Traumatol* 2009;25:358-366.
- Westesson PL, Katzberg RW, Tallents RH, Sanchez-Woodworth RE, Svensson SA. CT and MR of the temporomandibular joint: comparison with autopsy specimens. *Am J Roentgenol* 1987;148:1165-1171.
- Ludlow JB, Davies-Ludlow LE, Brooks SL. Dosimetry of two extraoral direct digital imaging devices: NewTom cone beam CT and Orthophos Plus DS panoramic unit. *Dentomaxillofac Radiol* 2003;32:229-234.
- Ludlow JB, Davies-Ludlow LE, Brooks SL, Howerton WB. Dosimetry of three CBCT devices for oral and maxillofacial radiology: CB Mercuray, NewTom 3G and i-CAT. *Dentomaxillofac Radiol* 2006;35:219-226.
- Honda K, Larheim TA, Maruhashi K, Matsumoto K, Iwai K. Osseous abnormalities of the mandibular condyle: diagnostic reliability of cone beam computed tomography compared with helical computed tomography based on an autopsy material. *Dentomaxillofac Radiol* 2006;35:152-157.
- Robinson B, Kelma V, Marques LS, Pereira LJ. Imaging diagnosis of the temporomandibular joint. *Oral Radiol* 2009;25(2):86-98.
- Eggers G, Klein J. Geometric accuracy of digital volume tomography and conventional computed tomography. *Br J Oral Maxillofacial Surg* 2008;46(8):639-644.
- Marques AP, Perrella A, Arita ES, Pereira MFSM, Cavalcant MGP. Assessment of simulated mandibular condyle bone lesions by cone beam computed tomography. *Braz Oral Res* 2010;24(4):467-474.
- Lindvall AM, Helkimo E, Hollender L, Carlsson GE. Radiographic examination of the temporomandibular joint. A comparison between radiographic findings and gross and microscopic morphologic observations. *Dentomaxillofac Radiol* 1976;5(1-2):24-32.
- Masood F, Katz JO, Hardman PK, Glaros AG, Spencer P. Comparison of panoramic radiography and panoramic digital subtraction radiography in the detection of simulated osteophytic lesions of the mandibular condyle. *Oral Surg Oral Med Oral Pathol Oral Radiol Endod* 2002;93:626-631.
- Honey OB, Scarfe WC, Hilgers MJ, Klueber K, Silverira AM, Haskell BS et al. Accuracy of cone-beam computed tomography imaging of the temporomandibular joint: Comparisons with panoramic radiology and linear tomography. *Am J Orthod Dentofacial Orthop* 2007;132(4):429-438.
- Delantoni A. Rheumatoid Arthritis of the Temporomandibular Joint; Comparison of Digital Panoramic Radiographs Taken Using the Joint Limitation Program [JLA View] and CT Scans. *Open Journal of Rheumatology and Autoimmune Diseases* 2012;2:59-63.

21. Ludlow JB, Davies KL, Tyndall DA. Temporomandibular joint imaging: a comparative study of diagnostic accuracy for the detection of bone change with biplanar multidirectional tomography and panoramic images. *Oral Surg Oral Med Oral Pathol Oral Radiol Endod* 1995;80:735-743.
22. Larheim TA. Current trends in temporomandibular joint imaging. *Oral Surg Oral Med Oral Pathol Oral Radiol Endod* 1995;80:555-576.
23. Cara ACB, Gaia BF, Perrella A, Oliveira JXO, Lopes PML, Cavalcanti MGP. Validity of single- and multislice CT for assessment of mandibular condyle lesions. *Dentomaxillofac Radiol* 2007;36:24-27.
24. Zain-Alabdeen EH, Alsadhan RI. A comparative study of accuracy of detection of surface osseous changes in the temporomandibular joint using multidetector CT and cone beam CT. *Dentomaxillofac Radiol* 2012;41:185-191.
25. Shoostari SS, Maserat V, Dabbaghi A, Shahab SH, Ebrahimi HS, Pourmahdi M et al. In-Vitro Comparison of the Diagnostic Accuracy of CBCT and Helical CT for Detection of Mandibular Condyle Erosions. *JIDA IRAN* 2014;26(1):1-8.
26. Hussain AM, Packota G, Major PW, Flores-Mir C. Role of different imaging modalities in assessment of temporomandibular joint erosions and osteophytes: a systematic review. *Dentomaxillofac Radiol* 2008;37:63-71.
27. Tsiklakis K, Syriopoulos K, Stamatakis HC. Radiographic examination of the temporomandibular joint using cone beam computed tomography. *Dentomaxillofac Radiol* 2004;33(3):196-201.
28. Koyama J, Nishiyama H, Hayashi T. Follow-up study of condylar bony changes using helical computed tomography in patients with temporomandibular disorder. *Dentomaxillofac Radiol* 2007;36(8):472-477.