

AN ASSOCIATED POLYDACTYLY WITH RIGA – FEDE DISEASE: A RARE CASE REPORT

Suman Basavraju¹, Kanika Gupta Verma², Metashi Singla³, Pradhuman Verma^{4,*}

¹Reader, Department of Periodontology; JSS Dental College, Mysore, Karnataka

²Reader, ³P.G Student, Department of Pedodontics & Preventive dentistry; Surendera Dental College, Sriganganagar, Rajasthan

⁴Reader, Department of Oral Medicine & Radiology, Surendera Dental College, Sriganganagar, Rajasthan

***Corresponding Author:**

Email: pradhuman_verma@rediffmail.com

ABSTRACT:

Riga-Fede disease occurs during early infancy and is characterized by a reactive traumatic lesion on ventral surface of the tongue. It results due to raking motion of tongue over the recently erupted natal, neonatal or primary mandibular incisors. The lesion causes pain during feeding practice, leading to nutritional deficiencies and retarded growth. The management includes conservative approach or extraction that promotes healing. This case report highlights the association of Riga-Fede disease with polydactyly in a two and half months old male child, along with the therapeutic approach to the condition.

Keywords: Riga Fede disease, Traumatic ulcer, Neonatal teeth, Polydactyly.

INTRODUCTION

Riga-Fede disease occurs during early infancy and is characterized by a reactive traumatic lesion on ventral surface of the tongue¹. It is an uncommon self-limiting persistent ulceration of the oral mucosa. The lesion was first described clinically by Riga in 1881 and in 1890 Fede added its histological description, thus named as Riga-Fede disease². The ulceration usually involves the ventral surface of tongue due to raking motion over the incisal edges of recently erupted natal, neonatal or primary mandibular incisors³. However the buccal mucosa, lingual frenum, floor of mouth, labial mucosa and even dorsal surface of tongue can get involved^{4,5}. Lesion appears as ulcer but can progress to an enlarged, fibrous mass with appearance of an ulcerative granuloma³. Usually, the lesion is seen within 6-8 months of age, being associated with natal or neonatal teeth, but it may also occur in infants upto 2 years of age due to repetitive tongue-thrusting habits and in children with familial dysautonomia⁶⁻⁸. The incidence of Riga-Fede disease in the presence of natal/neonatal teeth has been reported to be 6% to 10%⁸. The disease is associated with infection, dehydration, feeding problems leading to nutritional deficiencies. Thus, immediate management of disease is required, that includes composite addition or contouring of sharp incisal edges, extracting the associated tooth and modifying feeding behaviour with certain feeding appliances⁹. An early accurate diagnosis is mandatory to differentiate Riga-Fede disease from serious neurologic and hereditary disorders that also present similar oral ulcerations¹⁰. The present case report describes a rare occurrence of Riga Fede disease with polydactyly, and highlights its symptomatology and therapeutic approach.

CASE REPORT

A two and half months old boy was referred to the Department of Pedodontics and Preventive Dentistry by his paediatrician, with difficulty during feeding due to the presence of mandibular anterior teeth since birth. The infant's mother was concerned about the ulceration present on ventral surface of tongue, which she noticed around three weeks back. She observed that a feeding problem has developed and child cries often during feed. There was no history of any systemic problems, fever, dehydration and nutritional deficiencies. Prenatal, post natal and family history revealed no relevant findings. No developmental disorders or congenital syndromes were observed in his immediate family. General physical examination revealed an extra finger on both the hands of child (Figure 1). Intraoral examination revealed two natal teeth were present in the mandibular anterior region. The teeth were firmly attached and had sharp incisal edges that caused ulceration on the ventral surface of tongue. The lesion was round in shape having 2cm diameter, it was erythematous and raised, with an indurated border covered by yellowish white slough (Figure 2). There was no associated bleeding with the lesion. A biopsy of the lesion was not attempted due to the infant's young age. However, a diagnosis of Riga-Fede disease was made because of the distinctive clinical signs of disease and associated natal teeth. Although literature reported various cases of Riga Fede disease, but an association of polydactyly with Riga-Fede disease makes this case rare in occurrence.

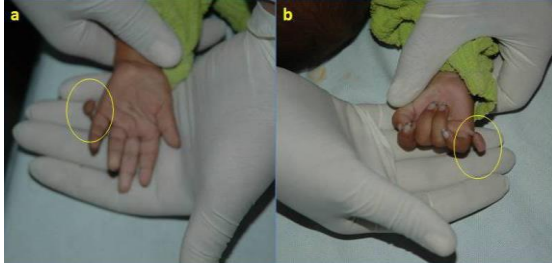


Figure no. 1: Polydactyly in relation to right and left hands of patient

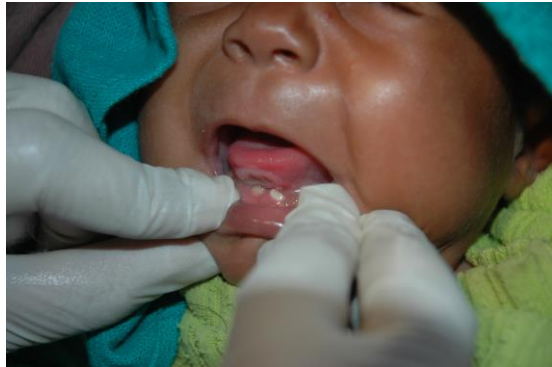

Figure no. 2: Intraoral photograph showing an indurated erythematous ulcerative lesion on the ventral surface of tongue.

A conservative management was planned by smoothing the incisal margins with the help of finishing stones attached to slow speed contraangle hand piece. The management of sharp incisal edge was combined with a therapeutic approach using a topical corticosteroid given for one week for its anti-inflammatory action. After one week, mother reported with improvement in feeding practice of child and ulcer showed signs of healing. Patient's guardians were advised to give follow up after every month, but they didn't reported back.

DISCUSSION

Many cases of infants have been reported with natal or neonatal teeth present at or within a month of birth respectively. Although early eruption is reported for primary mandibular central incisors most commonly, but some cases of premature eruption of primary maxillary incisors, canines and molars have also been observed¹¹. Various terms have been used for neonatal teeth such as congenital teeth, fetal teeth, predeciduous teeth, early teeth, Cardarelli's aphthae, and dentitia praecox^{11,12}. The most impending complication of natal and neonatal teeth is an ulceration caused by their rubbing against the ventral surface of the tongue. This condition is qualified as Riga-Fede disease, if patient is younger than two years of age. After that age, it should be called oral traumatic granuloma¹⁰. Riga-Fede disease is a reactive, traumatic mucosal lesion characterized

by persistent ulceration of the oral mucosa⁵. In the present case, the baby presented at two and half months of age and had two natal teeth in the mandibular anterior region. Based on close relation of the tooth to ulcer, a diagnosis of Riga-Fede disease was made.

The classic ulcer associated with Riga-Fede disease can also indicates the existence of underlying developmental or neurologic disorders like Riley-Day syndrome, Lesch-Nyhan syndrome and motor disorders.

The traumatic ulcer interferes with proper suckling and feeding that cause risk for nutritional deficiencies. So management of the disease is of prime concern for pedodontists. The treatment of lesion has varied over the years, from conservative to invasive management. The treatment options being recontouring of the sharp incisal edges of natal teeth, extraction of offending teeth and modifying feeding behaviour with feeding appliances^{11,13}. As extraction of natal/ neonatal teeth may cause space loss and collapse of developing arches, so a conservative treatment was planned. In the present case, conservative treatment was combined with therapeutic approach that resulted in healing of the lesion.

Histologic analysis of the ulcer usually reveals a chronic ulceration surrounded by a dense mixed inflammatory granulation tissue infiltrate consisting largely of lymphocytes, macrophages, mast cells and numerous eosinophils.

The literature reported various cases of Riga-Fede disease but till date no case has been reported with associated polydactyly. The patient reported with one extra finger attached to little finger on both the hands, diagnosing it to be a case of polydactyly. An association of Riga-Fede disease with polydactyly, reported it to be rare in its occurrence.

CONCLUSION

Various case reports have been reported in literature, but the association of Riga-Fede disease with polydactyly is rare in its occurrence. The natal and neonatal teeth are of prime importance to pedodontists, as their presence may be associated with various complications. The management of Riga-Fede disease is essential to maintain form and function of child's primary dentition.

REFERENCES:

1. Agrawal A, Parihar A, Ratre R, Singh M, Rawat A. Riga-Fede disease: a case report. *Arch Dent Sci* 2011;2:58-60.
2. Zaenglein AL, Chang MW, Meehan SA, Axeirod FB, Orlow SJ. Extensive Riga-Fede disease of the lip and tongue. *J Am Acad Dermatol* 2002;47:445-7.
3. Ceyhan AM, Yidirim M, Poasak PY, Akkaya VB, Ayata A. Traumatic lingual ulcer in a child: Riga-Fede disease. *Clin Exp Dermatol* 2008;34:186-8.

4. Baghdad ZD. Riga-Fede disease: report a case and review. *J Clin Pediatr Dent* 2001; 25:209-13.
5. Choi SC, Park JH, Choi YC, Kim GT. Sublingual traumatic ulceration (a Riga-Fede disease): report of two cases. *Dent Traumatol* 2009;25:e48-e50.
6. Eley KA, Watt-Smith PA, Watt-Smith SR. Deformity of the tongue in an infant: Riga-Fede disease. *Paediatr Child Health* 2010;15:581-2.
7. Buchanan S, Jenkins CR. Riga-Fede's syndrome: natal or neonatal teeth associated with tongue ulceration: case report. *Aust Dent J* 1997;42:225-7.
8. Hegde RJ. Sublingual traumatic ulceration due to neonatal teeth (Riga-Fede disease). *J Indian Soc Pedo Prev Dent* 2005;23:51-52.
9. Slayton RL. Treatment alternatives for sublingual traumatic ulceration (Riga-Fede disease). *Pediatr Dent* 2000;22:413-4.
10. Lee J, Mandel L. Riga-Fede Disease Case Report. *NY State Dent J* 2014;36-7.
11. Baldiwala M, Nayak R. Conservative Management of Riga-Fede disease. *J Dent Child* 2014; 81:103-6.
12. Zhu J, King D. Natal and neonatal teeth. *J Dent Child* 1995;62:123-8.
13. Machuca G, Rodríguez S, Vargas M, Suárez C, Bullón P. Management of Riga-Fede disease: a case report. *J Disabil Oral Health* 2007;8:28-30.