

RHINO-MAXILLARY FORM OF MUCORMYCOSIS CAUSING SINUSITIS: A RARE CASE REPORT WITH REVIEW OF LITERATURE

Sugandha Arya^{1*}, Sharanamma B², Neelkant Patil³, Anitha B.⁴, Sumit Bhateja⁵, Basavaraj⁶

¹3rd Year Post Graduate student, ^{3,4}Reader, ⁵Senior lecturer, ⁶Professor & Head of Dept.,
Department of Oral medicine and Radiology, Vyas dental college and hospital, Jodhpur.
²Professor and Head, Department of Periodontics, Vyas dental college and hospital, Jodhpur.

***Corresponding Author:**

E-mail: suggusuggu53@gmail.com

ABSTRACT:

Mucormycosis is a rare condition, posing diagnostic and therapeutic challenge for dental surgeons who may not be familiar with its clinical presentation. Immunocompromised are more likely to suffer from this disease. In dentistry, this condition gains increasing interest because of its first manifestation in the facial and oral tissue. Proper history, clinical examination with radiological and histopathological investigations lead to its early diagnosis. Surgical management along with the institution of specific antifungal therapy ensures a good prognosis, thereby reducing the fatal complications associated with this disease.

Keywords: *Invasive fungal sinusitis, Rhinomaxillarymucormycosis, Rhinocerebralmucormycosis.*

INTRODUCTION

Mucormycosis is an acute, fatal, rapidly spreading opportunistic infection affecting humans.¹ Rhizopus, Absidia, Rhizomucor and Mucor are the organisms most commonly isolated from patients who suffer from mucormycosis.² These fungi are saprophytic, ferrophillic and ubiquitous in nature, collectively known as Phycomycetes.³ Evolving changes in nomenclature and molecular taxonomy favors the use of the term "mucormycosis" or "entomophthoromycosis" over the inclusive name "zygomycosis" describing any invasive fungal infection caused by species of the former phylum Zygomycota.^{4,5} Platauf is credited with the first description of Zygomycosis in his paper entitled- 'Mycosis mucorina' in 1885.⁶ Predisposing conditions include diabetes mellitus, malignant hematological diseases, stem cell and organ transplant, neutropenia, iron overload, major trauma, corticosteroids, immunosuppressive medications, human immunodeficiency virus infection and chronic liver disease.⁴ Clinically, mucormycosis occurs in one of the four forms: Rhino cerebral, pulmonary, gastrointestinal and disseminated. Rhinocerebral form is the most common accounting for 30% to 50% of all cases of mucormycosis with Rhizopus being the predominant pathogen involved.^{7,8,9,10,11} This form has been predominantly associated with poorly controlled diabetes mellitus and diabetic ketoacidosis. Rhinocerebral form is further subdivided into two subtypes: a highly fatal rhino-orbito-cerebral form which is invasive and may involve the ophthalmic and internal carotid arteries and a less fatal rhino-maxillary form which involves the sphenopalatine and greater palatine arteries, resulting in thrombosis of the turbinate and necrosis of the palate.^{8,9,10} Infection begins in the nose and paranasal sinuses.¹⁰

It spreads due to inhalation, ingestion or contamination of traumatized mucosa like ulcer or extraction socket by fungal spores.¹² The fungus invades the arteries leading to thrombosis that subsequently causes necrosis of hard and soft tissues.¹³ Oral manifestations are usually in the palate where ischemic necrosis of the mucoperiosteum with bony denudation may occur, but the ulcers of mucormycosis have also been reported on the gingiva, lips, alveolar ridge, cheeks, tongue and mandible.^{14,7,8} This is a rare case report of an invasive mucormycosis of the maxilla leading to sinusitis.

CASE REPORT

A 54 year old male patient reported to the Dept. of Oral medicine and Radiology complaining of fluid discharge present from the nose from past 20 days. History reveals that the patient had pain and mobility in right upper back teeth region from past 6 months which was sudden in onset, dull, continuous in nature that aggravated on chewing food and on bending of head. It was accompanied by severe headache. Patient got his right upper back teeth extracted from a nearby practitioner but socket did not heal. After 4 months patient noticed presence of black area on hard palate with continuous dull pain present which usually aggravated on finger pressure. Patient got debridement done but 1 month later he noticed yellowish discoloration over the black area on the hard palate which lead to discomfort in chewing food. After 1.5 months loosening of upper front teeth with exposure of bone occurred along with mild swelling on right side of upper jaw. Patient got incisors extracted after 10 days with curettage and debridement but from past 20 days patient reported with clear fluid discharge from the nose that aggravated on drinking water leading to discomfort,

change in voice and halitosis with persistent headache. Slight burning sensation and epiphora in the eyes on eating spicy food was reported. No history of fever, paraesthesia was reported. Patient was known diabetic from past 7 months and is on insulin injections two times per day. A positive history of psoriasis from past 6 years was reported and patient was on topical steroid therapy for long period of time. On extraoral examination vital signs were within normal limits with appearance of generalised purplish papules/scales all over his limbs (Figure 1). On intra oral examination –right maxillary molars and maxillary incisors and left mandibular molars had been found to be missing. A solitary deep palatal ulcer roughly 2 x 2 cm in dimension was present 2cm posterior to the incisal papilla on the mid hard palate. It was rough with a sloping edge and was covered by yellowish necrotic slough with exposure of underlying bone. Surrounding tissues were observed to be inflamed. A large chunk of yellowish brown crusted necrotic bone was also present in the labial vestibular and alveolar ridge extending from mesial portion of right maxillary canine till the distal aspect of left maxillary canine along with inflammation and diffuse swelling present surrounding the right maxillary canine (Figure 2). On palpation, inspeactory findings were confirmed. It was firm, rough in texture with indurated border with positive tenderness. Surrounding tissues of exposed bone and swelling on the maxillary anterior ridge was found to be tender on palpation. Since, the lesion started 6 months back with necrosis and perforation of the palate associated with areas of inflammation and pain, a provisional diagnosis of osteomyelitis of the palate and differential diagnosis of deep fungal infection in the palate was given. Radiological investigations had been carried out to check for the extent and bony involvement. Maxillary cross-sectional occlusal radiograph and OPG (Figure 3) revealed large diffuse ill-defined radiolucency seen in the palate suggestive of erosion of bone. On PNS view, bilateral opacification of maxillary sinus was seen. CT PNS (Figure 4) revealed bilateral maxillary and sphenoid sinusitis causing blockage of osteomeatal units with focal hyperdense content in right maxillary sinus. Mucosal thickening in bilateral nasal cavities and posterior ethmoid air cells. CT of paranasal and oropharynx (Figure 5) revealed erosion of hard palate with ill-defined soft tissue adjoining it, erosion of pterygoid plates on either side, sphenoid bone with ill-defined nasopharyngeal and parapharyngeal soft tissue on either side with bilateral maxillary and sphenoid sinusitis. Contrast enhanced MRI of brain findings suggestive of sinusitis involving bacterial maxillary sinus, left ethmoid sinuses and sphenoid sinus without ant intracranial and intraorbital invasion. Deviated nasal septum with rhinitis. Biochemical investigations

revealed fasting blood sugar 230 mg/dl and post prandial blood sugar 360 mg/ml. Histopathological investigations were done which included a swab collection from palate. Potassium hydroxide (KOH) smear showed few budding yeast like cells and plenty of nonseptate branched hyphae. On Grams staining fungal elements were seen. Biopsy from the hard palate was done, it comprised two fragments, and one fragment was totally necrosed, other fragment shows hyperkeratosis, parakeratosis and hyperplastic squamous epithelium. Subepithelium showed focal areas of necrosis with occasional vessels showing fibronoid necrosis of vessel wall and obliteration of lumen. Periodic Acid Schiff (PAS) stain showed broad nonseptate filaments of fungi. Histopathologic features were suggestive of maxillary mucormycosis. Correlating clinical, radiological and histopathological findings, a final diagnosis of invasive mucormycosis of palate leading to sinusitis was given. Treatment comprised hospitalising the patient, controlling of blood sugar level with insulin and oral hypoglycemics, followed by debridement along with systemic antifungal therapy was prescribed - Tab variconazole 100 mg b.d. for 2 months and Inj amphotericin (total dosage 5025 mg) given for a period of 2.5 months. Obturator was given for the patient and patient was kept under follow up (Figure 6).

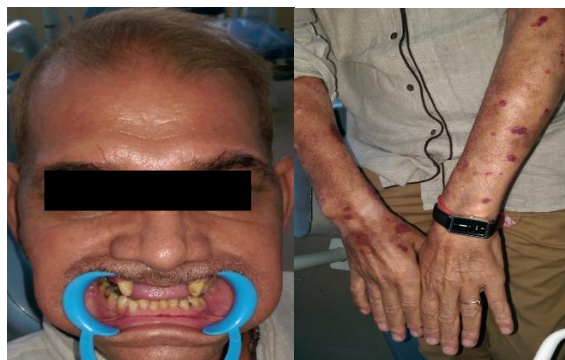
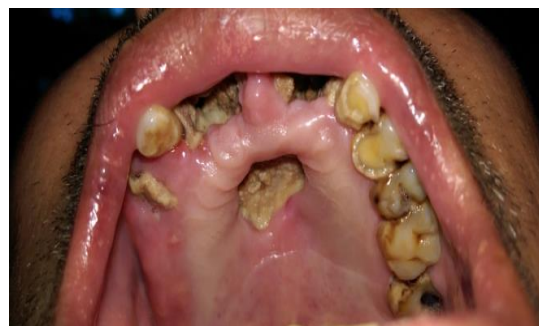
Figure 1: Showing purplish plaque/scales on limbs.



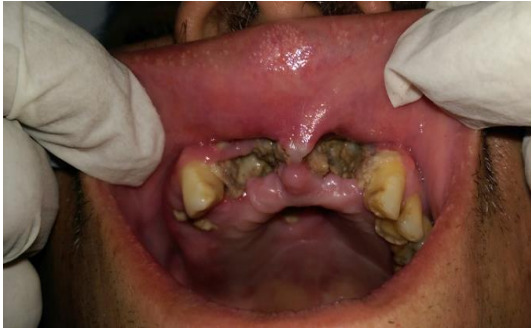

Figure 2: Showing palatal ulceration with exposed necrotic bone.

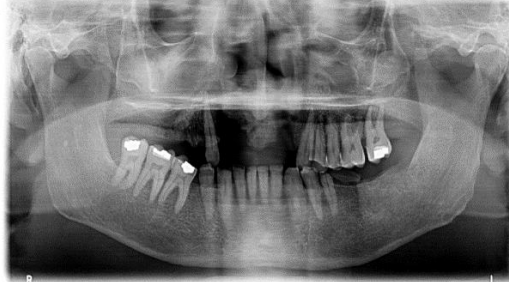
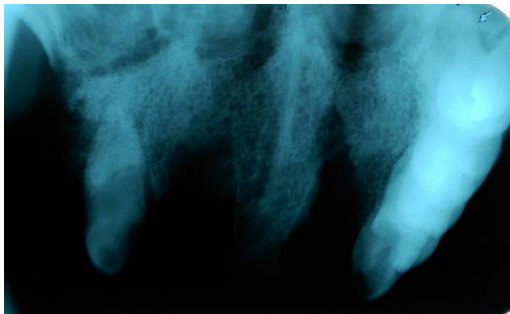


Figure 3: Occlusal and OPG showing ill-defined radiolucency in the palatal bone.

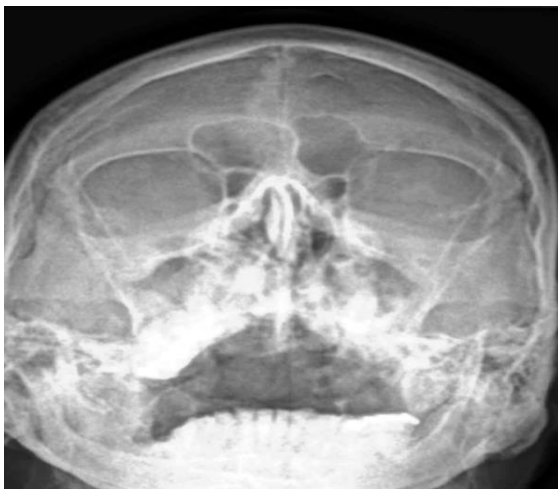

Figure 4: PNS showing bilateral opacification in maxillary sinus

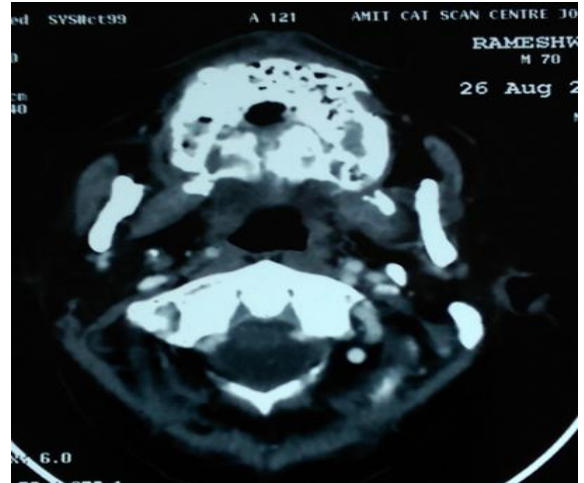


Figure 5: CT showing palatal perforation.

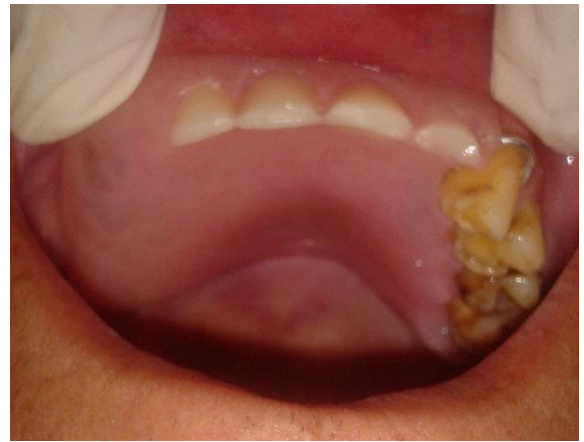

Figure 6: Obturator given.

DISCUSSION

Mucormycosis is an uncommon, fatal opportunistic infection caused by broad, nonseptate hyphae of the order mucorales. It is found worldwide in decaying vegetation and soil.¹ This order has become an increasingly important pathogen during the last two decades, due to the dramatic increase in patients with predisposing factors like diabetes mellitus and immunosuppressive therapy.⁴ Its occurrence in diabetic patients is due to various reasons like acidosis in these patients reducing the phagocytic capacity of granulocytes, increasing the free ferric ions availability which favors mucorales growth, enzyme ketoreductase of *Rhizopus* fungi utilizing available ketone bodies.¹⁵ The low pH, hyperglycemic state and iron rich environment in diabetics also favors fungal growth.¹⁶ The hallmark of this infection is tissue necrosis resulting from angioinvasion and subsequent thrombosis, with substantial associated morbidity and mortality.¹⁷ Most of the opportunistic mycosis is systemic, but mucormycosis frequently is localized.¹ The clinical presentation of Rhinomaxillary, a variant of rhinocerebral form is variable and the most common

symptoms of the rhinomaxillary form include proptosis, loss of vision, nasal discharge, sinusitis, palatal necrosis and perforation.^{8,10} Sometimes it may be associated with triad of symptoms of poorly controlled diabetes mellitus, antral sinusitis and facial gangrene.¹⁸ Black necrotic eschar on the palate or nasal cornet may be typically seen due to gangrene of the infected tissues.¹⁹ In literature, reports of mucormycosis state that the involvement of the hemipalate is uncommon, being rarely recorded in cases of rhinocerebralmucormycosis. Involvement of the oral cavity usually appears as palatal ulceration or necrosis and later as perforation of the palate as a result of infection in the nasal cavity or paranasal sinuses via palatal vessels. In the early stage of disease, patients often exhibit facial cellulitis and anesthesia, nasal discharge, necrotic turbinates, fever, headache and lethargy. However, the present case most of the clinical features (headache, nasal discharge, epiphora, palatal ulcer, necrotic bone, sinusitis) had been along with involvement of hemipalate during the course of the disease. Often there is a history of extraction of a maxillary tooth with pus discharge from an unhealed extraction socket and exposure of necrotic bone or a solitary palatal ulcer with exposed maxillary bone as the sole oral manifestation which had been reported in our case with preceding history of dental extraction followed by the appearance of palatal ulcer with necrosis of bone.²⁰ Usually the antrum is infected first and then through the sphenopalatine and greater palatine arteries, the palate is affected.²¹ In long standing diabetics with poor glycemic control, there is atherosclerosis and microangiopathy of blood vessels which further compromises the vascularity and predisposes the patient to osteomyelitis.²² The infection may spread from the antrum to the orbit through the nasolacrimal duct, blood vessels or the lamina papyracea. Even perineural invasion has been reported in some cases.²³ Further extension of the infection from the orbit to the brain occurs via orbital vessels or the cribriform plate. Through the apex of the orbit, invasion of the lateral wall of the cavernous sinus can occur, leading to cavernous sinus thrombosis, ischemia of the internal carotid artery, cerebral ischemia and subsequently death.¹⁹⁻²¹ Mucormycosis is a disease of the diseased and is not commonly seen in healthy people. However, immunocompetent individuals as a result of trauma or surgery might get infected by mucormycosis.²⁴ The rhinomaxillary form is the most common form of infection, predominantly occurring in patients with uncontrolled diabetes mellitus.^{25,26} In the case presented here, as our patient was landlord, he might have been infected from the soil and due to his immunocompromised state of diabetes and topical application of corticosteroids for psoriasis the fungi became virulent. Also, the infection did not spread to

other organ systems and without any intracranial and intraorbital invasion in spite of uncontrolled diabetes mellitus. Therefore, the case is of rhinomaxillary form of the disease which is a subdivision of the well-documented rhinocerebral form.⁸ Early diagnosis is critical because of rapid progression of this disease and is made on clinical findings, radiographic evaluation and identification of organisms by culture. Radiological features shows nodular thickening of sinus mucosa, cloudy sinusitis without fluid levels, spotty destruction of bony walls of paranasal sinuses are seen.²⁷ CT findings show opacification of paranasal sinuses, thickening of sinus mucosa and erosions of the bony walls.²⁸ CT and MRI will show destruction of bone in the areas involved.^{29,30} In MRI infected necrotic tissue is depicted as lack of enhancement with a characteristic 'black turbinate sign which may help in early diagnosis of this disease.³¹ Given the fulminating and invasive nature of the disease CT or MR images may be taken at frequent intervals disease to monitor the therapeutic response.³ The fungi can be difficult to find microscopically despite their large size, because the necrotic tissues examined usually do not present them. The hyphae are large (5-50 μ m), irregular width, right angles branching but not septate. They look like hollow tubes.¹ Mucormycosis is aptly diagnosed histologically when broad, irregularly shaped, nonseptate hyphae with right angle branching are seen invading the tissue with hematoxylin and eosin (H&E); but they are better visualized with PAS or silver stains.^{32,33} They are found mostly in areas adjacent to clinical necrosis, especially necrotic vessel wall as was depicted in our case. Clinically differential diagnosis of Wegener's granulomatosis, tuberculosis, squamous cell carcinoma, malignant salivary gland tumor and tertiary syphilis should be considered.^{10,27,29,30}

TREATMENT

Despite improvements in imaging modalities leading to earlier diagnoses and increasing therapeutic options, mucormycosis is still difficult to treat.⁴ It is a life-threatening infection and warrants emergency treatment. Management is based on prompt diagnosis and institution of early aggressive surgical and medical therapy. Treatment of the underlying systemic disease, especially control of the glycemic state or modification/cessation of immunosuppressive drugs help in decreasing the morbidity and mortality associated with mucormycosis.³⁴ Amphotericin B deoxycholate is the only antifungal agent licensed by the US Food and Drug Administration for primary therapy for mucormycosis and it is given intravenously (1-1.5 mg/kg daily)^{35,13} Amphotericin B is the polyene antifungal drug which binds to ergosterol in the fungal cell membrane altering its permeability. It is a

very toxic drug hence the patient has to be monitored for renal damage and anaphylaxis. Posaconazole is another antifungal drug, a triazole which is also very effective besides being safe for patients with renal disease.^{3,34} Since the involved blood vessels are ischemic, the antifungal drugs do not reach their target tissues hence extensive surgical debridement to remove necrotic tissue and establish sinus drainage is essential.³⁶ Hyperbaric oxygen therapy has been used as an adjunct to aggressive surgical debridement, amphotericin B therapy, control of any underlying predisposing conditions by aiding neovascularization and subsequent healing.³⁷ Granulocyte colony-stimulating factor may also be administered to improve host defences and also to enhance leukocyte count to promote immunity.³⁸

PROGNOSIS

Cases of localized sinonasalrhinocerebralmucormycosis have been reported to have low mortality rate (10%). Progression of the disease is associated with worse prognosis, with CNS involvement considered fatal.³⁹

CONCLUSION

Rhinomaxillarymucormycosis present a therapeutic and diagnostic dilemma in terms of its clinical presentation. They must be considered in the differential diagnosis of oral ulcerative and necrotic lesions in the maxilla/palate with or without pus discharge particularly in immunocompromised patients with a possible history of tooth extraction. If diagnosed at an early stage, complications associated with this fatal fungal infection can be minimised.

REFERENCES:

- Almeid O, Scully C. Fungal infections of the mouth. *Braz J Oral Sci.* 2002; 1(1):19-26.
- Eucker J, Sezer O, Graf B, Possinger K. Mucormycoses. *Mycoses.* 2001; 44:253-260.
- Mohanty N, Misra S, Sahoo S, Mishra S, Vasudevan V, S Kailasam. Rhinomaxillary Mucormycosis masquerading as Chronic Osteomyelitis: A Series of Four Rare Cases with Review of Literature. *Journal of Indian Academy of Oral Medicine and Radiology.* 2012;24 (4):315-323.
- Yue Dai, Walker J, Ruba A, Faisal A. Mucormycosis in two community hospitals and the role of infectious disease consultation: a case series. *International Journal of General Medicine.* 2013;6:833-838.
- U. Binder, E. Maurer and C. Lass-Flörl. Mucormycosis – from the pathogens to the disease. *ClinMicrobiol Infect.* 2014; 20 (Suppl. 6): 60–66.
- Paultauf A. Mycosis mucorina. *Virchows Arch Path Anat.* 1885;102:543-64.
- Jayachandran S, Krithika C. Mucormycosis presenting as palatal Perforation. *Indian J Dent Res.* 2006; 17:139-42.
- Woo SB, Greenberg MS. Ulcerative, vesiculous and bullous lesion. In: Greenberg MS, Glick M, Ship JA, editors. *Burket's Oral Medicine.* 11th Ed, India; B C Decker Inc Hamilton: 2008. P. 74-5.
- Doni R, Basavaraj V, Hassan T, Hippargi S. Sequence of oral manifestations in rhino-maxillaryMucormycosis. *Indian Journal of Dental Research.* 2011; 22(2): 331-335.
- AjitAuluck. Maxillary necrosis by mucormycosis: A case report and literature review. *Med Oral Patol Oral Cir Bucal.* 2007;12:e360-4.
- R Madan, D Barde, S Rawlani , R Chandak. Maxillary necrosis by mucormycosis: a rare case report. *J MGIMS.* 2013;18(1):67-70.
- Sammassimo S et al. Disseminated Mucormycosis in a Patient with Acute MyeloblasticLeukemia Misdiagnosed as Infection by Enterococcus faecium. *J ClinMicrobiol.* 2004; 42(1): 487–9.
- M Abidullah, G Kiran, Gaddikeri K, G Karpe, Bhavirisetty D. Uncommon Opportunistic Fungal Infections of Oral Cavity-Report of a Case of Rhino-Orbital Mucormycosis and Review of Literature. *J Res Adv Dent.* 2015; 4(1):51-55.
- Ramon Y, Oberman M, Horowitz I, Freedman A. Extensive maxillary Sequestration resulting from rhinocerebralmucormycosis. *J Oral Surg* 1977; 35:989-91.
- Aggarwal P, Saxena S, Bansal V. Mucormycosis of maxillary sinus. *J Oral MaxillofacPathol.* 2007; 11: 66-9.
- Skiada A, Pagano L, Groll A. Zygomyces in Europe: Analysis Of 230 cases accrued by the registry of the European Confederation Of Medical Mycology (ECMM) Working Group on Zygomycosis between 2005 and 2007. *ClinMicrobiol Infect.* 2011;17:1859-67.
- Ibrahim AS, Spellberg B, Walsh TJ, Kontoyiannis DP. Pathogenesis of mucormycosis. *Clin Infect Dis.* 2012;54 (Suppl 1):S16–S22.
- Garg R, Gupta VV, Ashok L. Rhinomaxillarymucormycosis: A palatal ulcer. *ContempClin Dent.* 2011;2:119-23.
- Pandey A, Bansal V, Asthana AK, Trivedi V, Madan M, Das A. Maxillary osteomyelitis by mucormycosis: Report of four cases. *Int J Infect Dis.* 2011;15(1):e66-69.
- Jayachandran S, Krithika C. Mucormycosis presenting as palatal Perforation. *Indian J Dent Res.* 2006;17:139-42.
- Shetty SR, Punnya VA. Palatal mucormycosis: A rare clinical Dilemma. *Oral Surg.* 2008;1(3):145-48.
- Mallis A, Mastronikolis SN, Naxakis SS, Papadas AT. Rhinocerebralmucormycosis: An update. *Eur Rev Med Pharmacol Sci.* 2010;14(11):987-92.
- Kim J, Fortson JK, Cook HE. A fatal outcome from rhinocerebralmucormycosis after dental extractions: A case report. *J Oral Maxillofac Surg.* 2001;59(6):693-97.
- Torres-Narbona M, Guinea J, Martinez-Alarcon J. Impact of Mucormycosis on microbiology overload: A survey study in Spain. *J ClinMicrobiol.* 2007;45:2051-53.
- Spellberg B, Edwards J Jr, Ibrahim A. Novel perspectives on Mucormycosis: Pathophysiology, presentation and management. *ClinMicrobiol Reviews.* 2005;18(3):556-69.
- Mcnulty JS. Rhinocerebralmucormycosis: Predisposing factors. *Laryngoscope.* 1982;92(10):1140-43.
- Wadhawan R, LuthraK, Yehoshuva R, Solanki G. Mucormycosis; deadlier infection: an overview. *ActaBiomedicaScientia.* 2015;2(1):11-15.
- Neill BM, Alessi AS, George EB, Piro J. Disseminated rhino cerebral mucormycosis, A case report and review of the literature. *J Oral Maxillofac Surg.* 2006; 64: 326-33.

29. Khan S, Jetley S, Rana S, Kapur P. Rhinomaxillary mucormycosis in a diabetic female. *J Cranio Max Dis.* 2013; 2: 91-3.
30. Mallis A, Mastronikolis SN, Naxakis SS, Papadas AT. Rhinocerebral mucormycosis: an update. *Eur Rev Med Pharmacol Sci.* 2010; 14(11):987-92.
31. Safder S, Carpenter JS, Roberts TD, Bailey N. The black Turbinate sign: An early MR imaging finding of nasal mucormycosis. *Am J Neuroradiol.* 2010;31:771-74.
32. Iatta R, Napoli C, Borghi E, Montagna MT. Rare mycoses of The oral cavity: A literature epidemiologic review. *Oral Surg Oral Med Oral Pathol Oral Radiol Endod.* 2009;108:647-55.
33. Marx RE, Stern D. Oral and maxillofacial pathology: A rationale For diagnosis and treatment (1st ed). Quintessence Publishing Co Inc. 2006;104-06.
34. Sugar AM. Agents of mucormycosis are and related species. In: Mandell, Bennett, Dolin (Eds). *Mandell, Douglas and Bennett's principles and practice of infectious diseases* (6th ed). Philadelphia, Pennsylvania USA: Elsevier Churchill Livingstone. 2005;2:2973-84.
35. Spellberg B, Ibrahim A, Roilides E, et al. Combination therapy for mucormycosis: why, what, and how? *Clin Infect Dis.* 2012;54 (Suppl 1): S73-S78.
36. Torres-Narbona M, Guinea J, Munoz P, Bouza E. Zygomycetes and zygomycosis in the new era of antifungal therapies. *Rev Esp Quimioter.* 2007;20:375-86.
37. Couch L, Theilen F, Mader JT. Rhinocerebral mucormycosis With cerebral extension successfully treated with adjuvant Hyperbaric oxygen therapy. *J Otolaryngol Head Neck Surg.* 1988; 114:791-94.
38. Liles WE, Huang JE, Van Bank JH, Bowden RA, Dale DC. Granulocyte colony-stimulating factor administered in vivo Augments neutrophil mediated activity against opportunistic Fungal pathogens. *J Infect Dis.* 1997;175:1012-15.
39. A. Mallis, S.N. Mastronikolis, S.S. Naxakis, A.T. Papadas. Rhinocerebral mucormycosis: an update. *European Review for Medical and Pharmacological Sciences.* 2010; 14: 987-992.