

Histopathological correlation with computed tomography in respect to evaluation of paranasal sinus diseases

Krishnakant Vaghela¹, Bhaven Shah^{2*}

¹Assistant Professor, ²Associate Professor, Dept. of Radiology, Gujarat Adani Institute of Medical Science, Bhuj, Kutch, Gujarat

***Corresponding Author:**

Email: researchguide86@gmail.com

Abstract

Introduction: Contrast enhanced CT scans are obtained only in patients who are acutely ill and suspected of having a complication of acute sinusitis. The present study was aimed to evaluate the spectrum of PNS diseases on CT and correlate their clinical and histopathological findings.

Materials & Methods: After fulfilling the necessary criteria for enrollment, first 100 patients with PNS diseases were included in the study. Patients who have failed medical management i.e., prolonged course of broad spectrum antibiotics for 3 weeks and trial of corticosteroid nasal spray, were included in the study. Patients with revision surgery were excluded from the study.

Results: The most common CT diagnosis was found to be chronic sinusitis (57/100), followed by fungal sinusitis (28/100) and lastly 10 cases of nasal polyp. The entire specimens were sent for histopathological examination.

Discussion & Conclusion: CT helps to delineate the anatomy of nose and sinuses, and drainage pathways of sinuses preoperatively. It is helpful in evaluating the site and extent of sinus pathology. Preoperative CT enabled the surgeon to visualize the drainage pathways, anatomical and critical variants in PNSs thus allowing effective management of the patient. However, a potential pitfall was its inability to accurately differentiate in cases of fungal sinusitis and high- density secretions.

Keywords: CT, Paranasal Sinus, Pathologies, Biopsy, Histopathology.

Introduction

The nose is the most prominent part of the face with functional and considerable aesthetic importance. Anatomical position of the nose and its passage have been considered as the direct route to the brain, individual's source of intelligence and spirituality. Presence of any mass in the nose and paranasal sinuses seems to be a simple problem; however it raises many questions about the differential diagnosis.⁽¹⁾

Pathological lesions of the paranasal sinuses include a wide spectrum of conditions ranging from inflammation to neoplasms both benign and malignant. These sinuses are in close anatomical relationship with orbit, cranial fossa and pterygopalatine fossa.⁽²⁾ Hence, early involvement of these areas is an important feature. Since clinical assessment is hampered by the surrounding bony structures, diagnostic radiology is of paramount importance.⁽³⁾

Plain radiography is the commonly used imaging modality for diagnosis of PNS diseases as it is economical, simple, and widely available. It can provide limited views of the anterior ethmoid cells along with the upper two-thirds of the nasal cavity.⁽⁴⁾ Computerized tomography (CT) is considered the gold standard for preoperative evaluation of PNS diseases for appropriate patient selection for functional endoscopic sinus surgery (FESS).^(4,5) It is mandatory to evaluate the PNS and nose by CT before planning for FESS. It can provide a "ROAD MAP" to direct the surgical approach to otolaryngologist. CT has some medico-legal importance as well. Computed tomography scan has become modality of choice for evaluation of peripheral nervous system (PNS)

pathologies as it optimally displays bony details, air and outlines soft tissue as well.⁽⁶⁾

Computed tomography proves to be the most reliable method of preoperative assessment of patients undergoing functional endoscopic sinus surgery (FESS) as it delineates the extent of the disease, define any anatomical variants and relationship of the sinuses with the surrounding important structures — thus providing a road map for sinus surgery.⁽⁷⁾

Coronal imaging plane offers the best visualization of the drainage pathways of the sinuses, whereas some drainage pathways (such as sphenoid sinus ostia) and sinus walls, oriented close to the coronal plane, are better seen on axial images.⁽⁸⁾ Contrast enhanced CT scans are obtained only in patients who are acutely ill and suspected of having a complication of acute sinusitis. The present study was aimed to evaluate the spectrum of PNS diseases on CT and correlate their clinical and histopathological findings.

Materials & Methods

The present study was conducted at Gujarat Adani Institute of Medical Sciences, Gujarat, India, for a period of 6 months. After fulfilling the necessary criteria for enrollment, first 100 patients with PNS diseases were included in the study. Patients who have failed medical management i.e., prolonged course of broad spectrum antibiotics for 3 weeks and trial of corticosteroid nasal spray, were included in the study. Patients with revision surgery were excluded from the study.

Methodology

All postoperative cases and patients with any traumatic conditions involving PNS were excluded from the study. A detailed clinical history including age, sex, occupation, duration of symptoms and specific complaints such as headache, nasal obstruction, nasal discharge, and facial pain were taken. Family history and personal history were also recorded. A thorough clinical examination was done, and obtained data were recorded, and a provisional diagnosis was prepared.

The detailed clinical assessment was performed, and their informed consent was obtained before subjecting them for the imaging modality. After fulfilling the desired criteria, all the selected patients, PNS was done. Computed tomography was done on 128 slice scanner (AS Siemens, Germany). Axial images were acquired using thin collimation, followed by reformats in all three planes, i.e., axial, coronal, and sagittal, with soft tissue and bony algorithms.

Results

Of the 100 patients included in the present study, 52 were females and 48 were males in the age group 10 to 50 years. Among the clinical symptoms, chronic nasal discharge was the most common symptom seen in 49 patients, postnasal drip in 63, followed by nasal obstruction in 58, anosmia in 28, headache in 40, and facial pain in 25 patients.

FESS was done in all patients in and biopsy specimen was taken for histopathological evaluation. The clinical, CT and histopathological diagnosis were recorded for their correlation and data analysis. The most common CT diagnosis was found to be chronic sinusitis (57/100), followed by fungal sinusitis (28/100) and lastly 10 cases of nasal polyp. The entire specimens were sent for histopathological examination. The diagnosis received was as follows: maximum cases were diagnosed as non specific inflammation (62%),

this was followed by inflammatory polyp (18%), fungal sinusitis (12%) and carcinomatous changes in (8%).

Table 1: Distribution of patients with sinus lesions in respect to CT diagnosis

| Diagnosis | CT (%) |
|-------------------|--------|
| Chronic Sinusitis | 57 |
| Fungal sinusitis | 28 |
| Nasal Polyp | 10 |
| Neoplastic | 5 |

CT: Computed tomography

Table 2: Distribution of patients of sinus lesion histopathology

| Histopathology Diagnosis | Frequency (%) |
|--------------------------|---------------|
| Chronic Sinusitis | 62 |
| Fungal sinusitis | 12 |
| Nasal Polyp | 18 |
| Neoplastic | 8 |

In the study, maxillary sinus was the most commonly involved sinus followed by ethmoid sinus, sphenoid sinus, and frontal sinus. Table 3

Table 3: Sinus distribution

| Sinus Involved | Number of Cases |
|----------------|-----------------|
| Maxillary | 85 |
| Ethmoid | 72 |
| Sphenoid | 43 |
| Frontal | 57 |

High sensitivity, specificity, positive and negative predictive values were noted in all diagnosis except fungal sinusitis. Table 4

Table 4: Diagnostic performance of computed tomography in comparison to histopathological diagnosis.

| Diagnosis | Sensitivity | Specificity | PPV | NPV | P |
|-------------------|-------------|-------------|------|------|--------|
| Chronic Sinusitis | 98.2 | 96.2 | 98.6 | 97.5 | <0.001 |
| Polyp | 94 | 98.3 | 97.5 | 98.3 | <0.001 |
| Fungal Infections | 60 | 90.2 | 44.2 | 97.8 | <0.001 |
| Neoplastic | 100 | 96.3 | 68.7 | 100 | <0.001 |

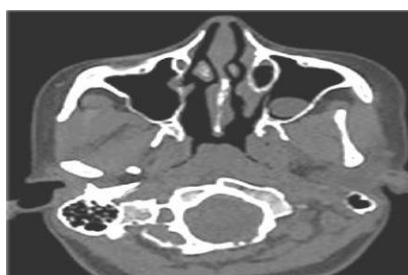


Fig.: Axial noncontrast computed tomography image in bone window showing polypoidal mass arising from lateral wall of the left maxillary sinus

Discussion

The majority of the cases were in the age group of 31–40 years and least number of patients were in age group of 61–70 years. There was a male predominance of 56.2% as compared to females 43.8%. Followed by nasal discharge, nasal obstruction, facial pain, and others. Kushwah et al. and Dewan et al. also noted similar findings their studies. They all concluded that a headache was the predominant presenting complaint. In the present study, maxillary sinus was the most commonly involved sinus followed by ethmoid, sphenoid and frontal. Kushwah et al., Maru and Gupta noted similar results in their studies.

Traditionally, plain films were the modality of choice in the evaluation of sinus pathology. In recent years, it has become evident that sinusitis is primarily a clinical diagnosis. The role of imaging is to document the extent of disease, to answer questions regarding ambiguous cases, and to provide an accurate display of the anatomy of sinonasal system. Today, CT has become the modality of choice for imaging evaluation of the morphology in this area.⁽⁹⁾

It is now generally accepted that CT is the optimum imaging method of demonstrating simple inflammatory disease to neoplasms in the paranasal sinuses. Clinical assessment can be used to evaluate acute sinus infection and CT is used for the investigation of persistent and chronic sinus disease refractory to medical therapy.⁽¹⁰⁾ Computed tomography evaluates the osteomeatal complex anatomy which is not possible with plain radiographs. Removal of disease in osteomeatal complex region is the basic principle of FESS which is best appreciated on CT scan.

In the present study it was found that most common CT inflammatory pattern was sinonasal polyposis, followed by infundibular pattern, osteomeatal pattern, spenoethmoidal recess pattern and lastly sporadic pattern. According to the study conducted by Chaitanya et al, it was reported that sinonasal polyposis pattern was the most common followed by infundibular and sporadic pattern in last.

In the present study good correlation was noted in cases of chronic sinusitis, polyp and neoplastic lesions,

as evident by high sensitivity and specificity vales. However poor correlation was obtained in cases of fungal sinusitis which was supported by low sensitivity.

Similar results were noted when positive and negative predictive values were calculated for all diagnosis.

Conclusion

CT helps to delineate the anatomy of nose and sinuses, and drainage pathways of sinuses preoperatively. It is helpful in evaluating the site and extent of sinus pathology. Preoperative CT enabled the surgeon to visualize the drainage pathways, anatomical and critical variants in PNSs thus allowing effective management of the patient. However, a potential pitfall was its inability to accurately differentiate in cases of fungal sinusitis and high-density secretions.

References

1. Dhillon V, Dhingra R, Davessar J, Chaudhary A, Monga S, Kaur M, Arora H: Correlation of clinical, radiological and histopathological diagnosis among patients with sinonasal masses. *International Journal of Contemporary Medical Research* 2016,3:1612-15.
2. Weber AL, Stanton AC: Malignant tumors of the paranasal sinuses: radiologic, clinical, and histopathologic evaluation of 200 cases. *Head & Neck* 1984,6:761-76.
3. Parsons C, Hodson N: Computed tomography of paranasal sinus tumors. *Radiology* 1979,132:641-5.
4. Kanwar SS, Mital M, Gupta PK, Saran S, Parashar N, Singh A: Evaluation of paranasal sinus diseases by computed tomography and its histopathological correlation. *Journal of Oral and Maxillofacial Radiology* 2017,5:46.
5. Branch I: Endoscopic Findings and Radiological Appearance in Chronic Rhinosinusitis-A Comparative Study.2012.
6. Chaita CS: Computed Tomographic Evaluati. 2015.
7. Vining EM, Yanagisawa K, Yanagisawa E: The importance of preoperative nasal endoscopy in patients with sinonasal disease. *The Laryngoscope* 1993,103:512-9.
8. Zinreich SJ, Kennedy DW, Rosenbaum AE, Gayler B, Kumar A, Stammberger H: Paranasal sinuses: CT imaging requirements for endoscopic surgery. *Radiology* 1987,163:769-75.
9. Josephson JS: Update on diagnosis and treatment of sinus disease: the functional endoscopic sinus surgery approach. *Medical Clinics of North America* 1991,75:1293-309.
10. Slavin RG, Spector SL, Bernstein IL, Kaliner MA, Kennedy DW, Virant FS, Wald ER, Khan DA, Blessing-Moore J, Lang DM: The diagnosis and management of sinusitis: a practice parameter update. *Journal of Allergy and Clinical Immunology* 2005,116:S13-S47.