

MORPHOLOGICAL ANALYSIS OF FORAMEN MAGNUM FOR GENDER DETERMINATION BY USING COMPUTED TOMOGRAPHY

Chandramani B. More^{1,*}, Nairita Saha², Ritika Vijayvargiya³

¹Professor & Head, ²Post Graduate Student, Dept. of Oral Medicine and Radiology, K.M. Shah Dental College & Hospital, Sumandeep Vidyapeeth University, Piparia, Vadodara, Gujarat, India

***Corresponding Author:**

E-mail: drchandramanimore@rediffmail.com, drmorechandramani@rediffmail.com

ABSTRACT

Background: Radiographs and advance imaging of orofacial structures are routinely used for personal identification. Ante-mortem and post-mortem radiographs are essential in cases of human remains and computed tomography plays a significant role in such situations.

Aim: To determine the gender from foramen magnum using computed tomography scan.

Settings and Design: The retrospective study was conducted by assessing the radiographic records, available in the archives of department.

Method and Material: Two hundred and fifty computed tomography (CT) scans of head and neck region were considered for morphometric analysis of foramen magnum using Syngo CT 2009E software.

Statistical analysis: The analysis was performed by using ANOVA, chi-square, independent 't' test and discriminate function analysis.

Results: The CT scan images of participants ranged from 08-79 years of age with equal number of males and females. The mean dimensions of foramen magnum in different age group was statistically not significant ($p > 0.05$). The total mean length of foramen magnum was 35.64 ± 3.39 mm and mean width was 29.17 ± 2.89 mm. The mean dimensions of foramen magnum were higher in males and was highly significant ($p < 0.001$). The co-relation of gender with morphology of foramen magnum was significant ($p < 0.05$). The accuracy for diagnosing male and female from dimension was 80% and 75.2% respectively. But the accuracy for gender identification from length and width was 74% and 70% respectively.

Conclusion: Personal identification is possible from the dimensions of foramen magnum and computed tomography plays a vital role.

Keywords: Computed tomography, Forensic radiology, Foramen magnum, Gender estimation, Personal identification.

INTRODUCTION

Identification of unknown individual has always been of paramount importance to the society and is important in calamities, forensic anthropology, anatomy and court of law.¹ Identification plays a significant role in forensic odontology by using different parts of orofacial structures either through radiographs or from clinical and pathological examination because of its uniqueness.² Gender determination is extremely important as it can positively rule out certain percentage of possibilities instantly.³ Determining sex in unidentified skeletons is not all the time an easy and correct procedure. Radiography can help in giving accurate dimensions and have multiple useful identification markers.^{4,5} Foramen magnum (FM) is one such important marker for sexual dimorphism (fig. 1).⁶ Ante-mortem and post-mortem radiographs are essential in cases of human remains and computed tomography (CT) scan plays a significant role in such situations.⁷ The craniometric points can be located and accurate measurements are achieved from CT scan images than on conventional radiographs.^{8,9} CT scan has minimal superimposition of structures and allows better visualization of minute differences of density.^{9,10}

The existing literature reveals numerous studies on dry skull using foramen magnum but very few have reported using CT scan. The present study was designed to determine gender from foramen magnum through computed tomography.

SUBJECTS AND METHODS

The present hospital based retrospective study was conducted with the permission of Institutional Ethics Committee of Sumandeep Vidyapeeth University with protocol number SVIEC/ON/DENT/RP/1504, dated 07/07/2014. The CT scan images of head and neck (axial view) of total two hundred and fifty healthy participants, available in the archives of department were included for morphometric analysis of foramen magnum. Each image was subjected for measurements, in millimetre using Syngo CT 2009E software (fig. 2& 3). The collected data was subjected to statistical analysis using SPSS software version 16 and the test applied were ANOVA, chi-square, independent 't' test & discriminant function analysis.

RESULTS

The age of participants in the present study ranged from 08-79 years with a mean of 35.96 ± 15.02 years and with equal number of males ($n=125$)

and females (n=125) (Graph 1). The minimum and maximum length of foramen magnum was 18.30 mm & 44.90 mm respectively; whereas the minimum and maximum width of foramen magnum was 18.60 mm and 37.80 mm respectively. The mean length and width of foramen magnum when core lasted with different age group, the values were statistically analysed by using ANOVA test and was found to be not significant ($p>0.05$). The total mean length of foramen magnum was 35.64 ± 3.39 mm and total mean width was 29.17 ± 2.89 mm (Table 1).

In our study, it was distinctly observed that the mean length and width of foramen magnum in males ($L= 37.54 \pm 2.57$ mm, $W= 30.57 \pm 2.42$ mm) was more when compared with females ($L= 33.75 \pm 3.04$ mm, $W= 27.78 \pm 2.65$ mm). These values were statistically analysed by using independent 't' test and was found to be highly significant ($p<0.001$) (Table 2).

The dimensions of foramen magnum when correlated with gender, the statistical analysis was highly significant ($p<0.001$). The stepwise discriminant function analysis was performed to differentiate male and female using dimensions of foramen magnum (Table 3).

The accuracy for gender determination was obtained by using Canonical Discriminant Function for Coefficient and constant value from the dimensions of foramen magnum. The formula used was $Y = A + (B \times X)$. ['Y' signifies estimated gender, 'A' signifies canonical discriminant function coefficient value of constant, 'B' signifies canonical discriminant function coefficient value and 'X' signifies length or width of foramen magnum].

For length: Estimated gender = $-12.657 + (0.355 \times \text{foramen magnum length})$

If they obtained discriminant function value is near to 0.672, then the person is probably discriminate by male and if they obtained discriminant function value is near to - 0.672, then the person is probably discriminate by female.

For width: Estimated gender = $-11.502 + (0.394 \times \text{foramen magnum width})$

If they obtained discriminant function value is near to 0.550, then the person is probably discriminate by male and if they obtained discriminant function value is near to - 0.550, then the person is probably discriminate by female.

We could correctly diagnose 75.2 % of males and 72.8 % of females from length of foramen magnum with an overall accuracy of 74 % in diagnosing gender. Also from width, 68 % of males

and 72 % of females were correctly diagnosed; with an overall accuracy of 70 % in diagnosing gender (Table 4).

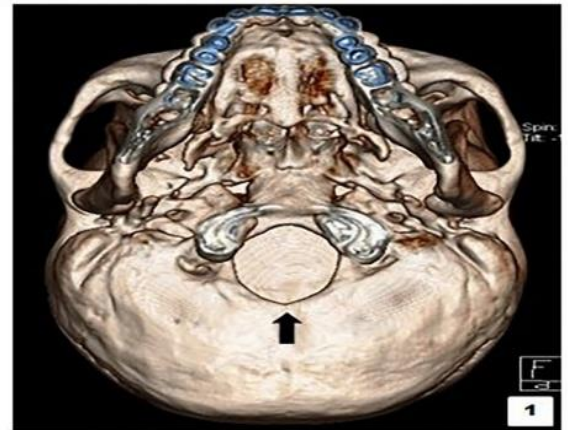


Fig. 1: 3D reconstructed computed tomography scan - axial view shows foramen magnum (black arrow).

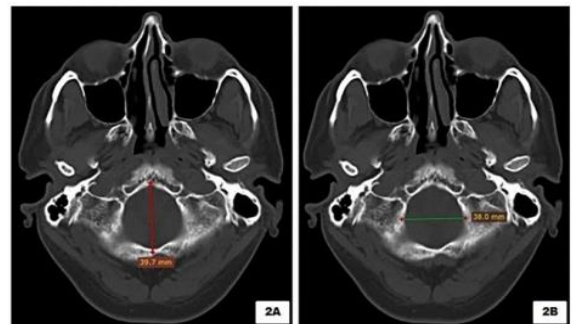


Fig. 2: Computed tomography scan - axial view shows length (fig. 2A) and width (fig. 2B) of foramen magnum.

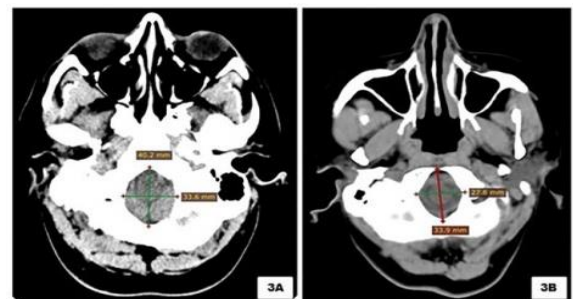


Fig. 3: Computed tomography scan - axial view shows measurements of foramen magnum in male (fig. 3A) and female (fig. 3B) participant.

Table 1: Co-relation of morphological of foramen magnum with different age group

Parameters	Age (in Years)	n	Mean (mm)	Std. Deviation	Std. Error	95% Confidence Interval for Mean		Minimum (mm)	Maximum (mm)	p-value (p<0.05)
						Lower Bound	Upper Bound			
Length	0-9	2	36.00	6.93	4.90	-26.2604	98.2604	31.10	40.90	0.827 Not significant
	10-19	20	35.70	3.38	0.75	34.1231	37.2869	30.10	41.50	
	20-29	71	36.11	2.83	0.34	35.4394	36.7804	29.40	42.90	
	30-39	65	35.30	4.06	0.50	34.2973	36.3089	18.30	44.10	
	40-49	34	35.19	3.65	0.63	33.9157	36.4667	28.10	44.90	
	50-59	34	35.34	3.51	0.60	34.1122	36.5643	27.90	42.80	
	60-69	17	36.00	1.70	0.41	35.1252	36.8748	32.70	38.00	
	>=70	7	36.57	2.75	1.04	34.0292	39.1136	33.30	40.00	
Total	250	35.64	3.39	0.21	35.2200	36.0648	18.30	44.90		
Width	0-9	2	27.85	0.64	0.45	22.1322	33.5678	27.40	28.30	0.241 Not significant
	10-19	20	29.45	2.86	0.64	28.1105	30.7895	24.50	35.10	
	20-29	71	29.93	2.60	0.31	29.3163	30.5456	24.30	35.20	
	30-39	65	28.92	3.37	0.42	28.0846	29.7554	18.60	37.80	
	40-49	34	28.71	3.17	0.54	27.6039	29.8137	23.70	35.90	
	50-59	34	28.69	2.50	0.43	27.8197	29.5685	23.60	33.70	
	60-69	17	28.45	2.13	0.52	27.3511	29.5430	25.10	31.90	
	>=70	7	29.77	2.52	0.95	27.4362	32.1067	27.00	33.20	
Total	250	29.17	2.89	0.18	28.8131	29.5333	18.60	37.80		

(n = number, mm = millimeter, Std= Standard, p= Probability value)

Table 2: Co-relation of dimensions of foramen magnum with gender

Parameters	Gender	n	Mean (mm) \pm Std Deviation	Std. Error mean	t	p-value (p<0.05)	Significance
Length	Male	125	37.54 \pm 2.57	0.23	10.632	<0.001	Highly Significant
	Female	125	33.75 \pm 3.04	0.27	10.632	<0.001	Highly Significant
Width	Male	125	30.57 \pm 2.42	0.22	<0.001		Highly Significant
	Female	125	27.78 \pm 2.65	0.24	<0.001		Highly Significant

(n = number, mm = millimeter, Std= Standard, p= Probability value)

Table 3: Stepwise discriminant function analysis using length and width of foramen magnum

Parameter	Wilks' Lambda	Eigen Value	Chi-square	Df	Obtained p-value	Significance (<0.05)
Length	0.687	0.456	92.955	1	<0.001	Highly Significant
Width	0.767	0.305	65.791	1	<0.001	Highly Significant

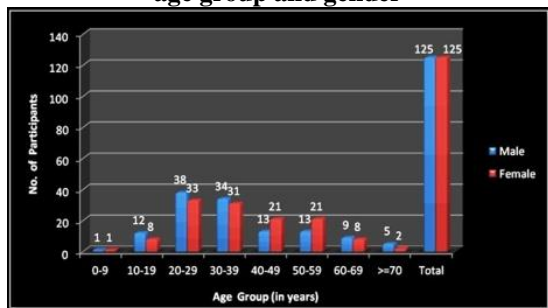
(df = Degree of Freedom, p= Probability value)

Table 4: Canonical discriminant function using length and width of foramen magnum

Parameter	Constant	Coefficients Value	Accuracy
Length	-12.657	0.355	74 %
Width	-11.502	0.394	70 %

(% = percentage)

Graph 1: Distribution of participants according to age group and gender



DISCUSSION

Foramen magnum is present at the base of the skull and is of interest for anthropology, anatomy, forensic medicine, and other medical fields.¹¹ It is the primary centre of ossification during growth and development. The ossification is completed by the age of 3 - 4 years and the fusion by 7 years. Usually the dimensions of FM will remain constant after second decade of life and will differ in male and female. It is a three dimensional, oval or circular apertures within the basal central region of the occipital bone.¹²⁻¹⁴ The location of FM plays a vital role in understanding of human evolution.^{15,16} The thickness of the cranial base and the anatomical position of FM, prevents any damage due to physical insult and inhumation. The skull and especially the skull base, has been analyzed with differing results and the levels of achievement in forensic related work.¹⁷⁻¹⁹

The morphometric analysis of foramen magnum revealed minimum (L=18.30 mm, W= 18.60 mm) and maximum (L=44.90 mm, W=37.80 mm) length and width which was statistically not significant ($p>0.05$). The total mean length (35.64 ± 3.39 mm) was higher than mean width (29.17 ± 2.89 mm) of foramen magnum. Also, the co-relation of dimensions of foramen magnum with age could not be ascertained.

Our study revealed that there is significant correlation between dimension of foramen magnum and gender. The length and width in males was considerably higher as compared to females (fig. 3). This observation matched with the findings of Uthman et al.⁸ Further we noted that even by discriminant function analysis test, the correlation was statistically highly significant ($p<0.001$). Our study had derived an equation $Y = A + (B \times X)$ for determining the accuracy for gender and we could correctly diagnose 75.2 % of males and 72.8 % of females from length of foramen magnum with an overall accuracy of 74 % in diagnosing gender. Also from width, 68 % of males and 72 % of females were correctly diagnosed; with an overall accuracy of 70 % in diagnosing gender. Thus, from overall dimension of foramen magnum, the accuracy for diagnosing

male and female was 80% and 75.2% respectively. Our finding was contradictory with the findings of Uthman et al⁸ wherein 90.7% of males and 73.3% of females were correctly diagnosed.

The results of our study indicate that foramen magnum is important in gender determination, although other oro facial structures are also helpful.

The results may vary geographically and depending on skeletal structure, arising due to genetic, environmental and nutritional factors.

CONCLUSION

The role of foramen magnum in diagnosing unknown person is notable and should be used in day-to-day practice of forensic radiology. The findings of the present study would enhance the knowledge and would help in identifying human remains when other identifying methods are inconclusive.

REFERENCES

1. Lynnerup N. Forensic Anthropology and Human Identification. Scandinavian Journal of Forensic Science.2013; 19(1):16-38.
2. Singh P, Oberoi S, Gorea R, Kapila A. Age Estimation in Old Individuals by CT Scan of Skull. JIAFM, 2004; 26(1):1-4.
3. Manoel C, Prado F, Caria P, Groppo F. Morphometric analysis of the foramen magnum in human skulls of brazilian individuals: its relation to gender. Braz. J. Morphol. Sci.2009; 26(2):104-108.
4. Chandrasekhar T, Vennila P. Role of Radiology in Forensic Dentistry. Journal of Indian Academy of Oral Medicine and Radiology. 2011;23(3):229-231.
5. Kadu S, Patil V. Forensic Radiology in India: current trends. Indian Journal of Basic & Applied Medical Research.2012;1(2):148-152.
6. Santhosh C, Vishwanathan K, Ashok G, Siddesh R, Tejas J. Morphometry of the Foramen Magnum: An Important Tool in Sex Determination. Research and Reviews: Journal of Medical and Health Sciences. 2013; 2 (4):88-91.
7. Jablonski N, Shum B. Identification of Unknown Human Remains by comparison of Ante-mortem and Post-mortem Radiographs. Forensic Science International. 1989;42(3):1-11.
8. Uthman A, Al-Rawi N, Al-Timimi J. Evaluation of foramen magnum in gender determination using helical CT scanning. Dentomaxillofacial Radiology,2012; 41, 197-202.
9. White S, Pharaoh M. Oral Radiology Principles and Interpretation, 6th edition. Philadelphia, Mosby Elsevier, 2010.
10. Karjodkar F. Textbook of Dental & Maxillofacial Radiography, 2nd edition. New Delhi, Jaypee, 2011.
11. Radhakrishna S, Shivarama C, Ramakrishna A, Bhagya B. Morphometric analysis of foramen magnum for sex determination in South Indian population. NUJHS. 2012;2:20-2.
12. Stand ring S. Gray's Anatomy the Anatomical Basis for Clinical Practices. 39th edition. London, UK: Elsevier Churchill Living Stone Publishing Company, 2008.

13. Faruqi N. A. Human osteology. Chapter 40. 2nd edition. CBS Publishers & Distributors Pvt. Ltd. 2011: 396-428.
14. Singh I. textbook of Human osteology. Chapter 6. 2nd edition. JAYPEE brothers medical publishers (P) Ltd, 2002 : 119 – 165.
15. Singh G, Talwar I. Morphometric analysis of foramen magnum in human skull for sex determination. International Peer Reviewed Journal of Biological Anthropology. 2013; 2(1):29-41.
16. Gruber P, Henneberg M, Boni T, Ruhli F. Variability of Human Foramen Magnum Size. The Anatomical Record, 2009; 292:1713–1719.
17. Kanchan T, Gupta A, Krishan K. Craniometric Analysis of Foramen Magnum for Estimation of Sex. World Academy of Science, Engineering and Technology.2013;79:500-3.
18. Jain D, Jasuja O, Nath S. Evaluation of foramen magnum in sex determination from human crania by using discriminant function analysis. El Mednifico Journal. 2014; 2 (2):89-92.
19. Ukoha U , Egwu O, Okafor I, Anyabolu A et al. Sexual Dimorphism in the Foramen Magnum of Nigerian Adult. Int J Biol Med Res. 2011; 2(4): 878 – 881.