

## Intraoral hydatid cyst: A review

Chandra Shekhar Jha<sup>1\*</sup>, Rupam Sinha<sup>2</sup>, Suman Sen<sup>3</sup>, Harshvardhan Jha<sup>4</sup>

<sup>1</sup>Assistant Professor, <sup>2</sup>Professor and HOD, <sup>3</sup>Reader, <sup>4</sup>PG Student, <sup>1</sup>Dept. of Microbiology, <sup>2-4</sup>Dept. of Oral Medicine and Radiology, <sup>1</sup>Government Medical College, Bettiah (West Champaran) Bihar, <sup>2-4</sup>Haldia Institute of Dental Sciences and Research, West Bengal, India

**\*Corresponding Author: Chandra Shekhar Jha**

Email: harshvardhan.spartan@gmail.com

### Abstract

Parasites have always been a point of interest for the medical fraternity. They cause numerous amount of diseases around the globe and are of prime importance of studies of major health organisations like WHO and CDC. Hydatid cyst are one of the commonest occurring cysts affecting the world population. However the oral complications has been less studied because of its rare occurrence in that region. This review article deals with the life cycle, intra oral complications along with diagnosis and treatment of such cysts.

**Keywords:** Parasites, WHO, CDC, Rare.

### Introduction

Parasites are a vast group of microorganisms that has been infecting mankind for thousands of years. These are group of non-vertebrates and are mainly included under classes protozoa, platyhelminthes, arthropoda.

Centre for Disease Control and Prevention (CDC); USA has defined parasites as;” an organism that lives on or in a host organism and gets its food from or at the expense of its host. CDC classifies parasites into 3 main classes based upon their potential to act on human beings:<sup>1</sup>

1. Protozoa
2. Helminths
3. Ectoparasite

Hydatid cysts are one of the commonest cysts caused by parasites. These are caused by *Echinococcus granulosus* or dog tape worm. The adult form of this parasite was discovered by Hartmann (1695) and Goeze (1782). It has worldwide distribution and has been recorded in Asian countries including India as well. It is generally found in liver, skin, brain etc. however 2% cases have been reported in the oral region.<sup>1</sup>

The primary hosts are the members of the canids family and human and other livestock acts as the intermediate host.<sup>1</sup> Cases in the oral and maxillofacial regions are very rare however few cases in the literature has been reported in neck region<sup>2</sup>, infratemporal region,<sup>3</sup> mandible,<sup>4</sup> tongue,<sup>2</sup> floor of the mouth<sup>5</sup> and buccal mucosa.<sup>6</sup>

### General Structure

The adult parasite is 3-6mm long. The body of the adult parasite has a scolex (head) with 4 suckers along with a rostellum and hook. It has a strobila which contains 3 segments called proglottids. The 3 proglottids (segments) are named immature, mature and gravid. The terminal segment containing the gravid proglottid is by far the biggest measuring 2-3mm in length and 0.6mm in breadth. A gravid proglottid on an average produce 823 eggs.<sup>1</sup> [Fig. 1]

The larval form represents the structure of the scolex in future adults and remains invaginated within a vesicular body. On entering the definitive host the scolex with 4

suckers and rostellar hooklets becomes evaginated and develops into adult worm.<sup>1</sup>

### Egg

Ovoid in shape. 32-36 micrometer in length and 25-32 micrometer in breadth and contains a hexacanth embryo with 3 pairs of hooks. Eggs are infective to man, sheep, cattle etc.<sup>1</sup>

### Life Cycle

This parasite completes its life cycle in 2 hosts. The definitive host is the canids family (dogs, foxes, wolfs etc.) and intermediate host is human and livestock (cattle especially).

The adult form of *Echinococcus* is present in the intestine of dogs and other members of canids family. The gravid proglottids produce a large number of eggs which are discharged via faeces of these animals. These eggs are ingested by the intermediate hosts (cattle, livestock) while grazing in the field and sometimes man as well due to intimate handling of dogs. The eggs travel to the intestine of the intermediate hosts and upon reaching the duodenum the hexacanth embryos hatch out. About 8 hours after ingestion the embryos bore their way through the intestinal wall and reach the sinusoidal capillaries. Some embryos pass through hepatic capillaries and enter the pulmonary circulation. Some pass through the pulmonary capillaries and enter the systemic circulation. They chiefly lodge in liver and lungs though other organs are invaded as well. Wherever the embryo settles it forms a cyst known as Hydatid cyst. The young larva gets transformed into a hollow bladder (drop of water shaped meaning *hydatis* in Greek). From inner side of the cyst brood capsules develop with a number of scolices. They eventually become fertile and when ingested by dogs and other canids; the definitive host they are capable of growing into adult worms in 6-7 weeks in the intestine of the definitive host. The cycle repeats itself.<sup>1,7</sup> [Fig. 2]

Human beings are infected when they accidentally ingest the ova passed in the stool of canids or the food contaminated by ova or by contact with infected canids.<sup>1,6,7</sup>

## Structure and Life Cycle of the Parasite

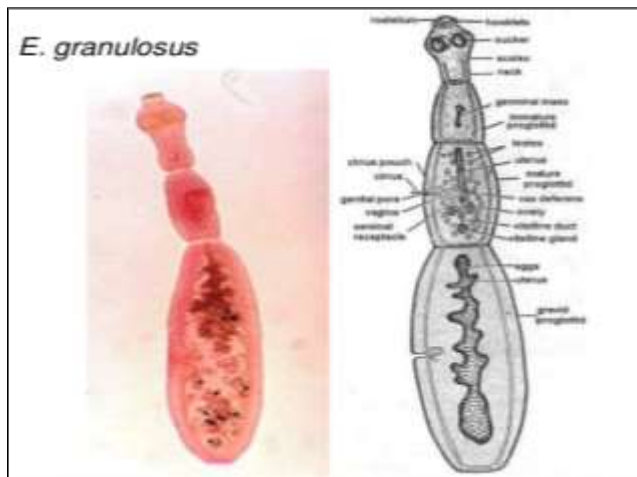


Fig. 1: Adult worm- echinococcus

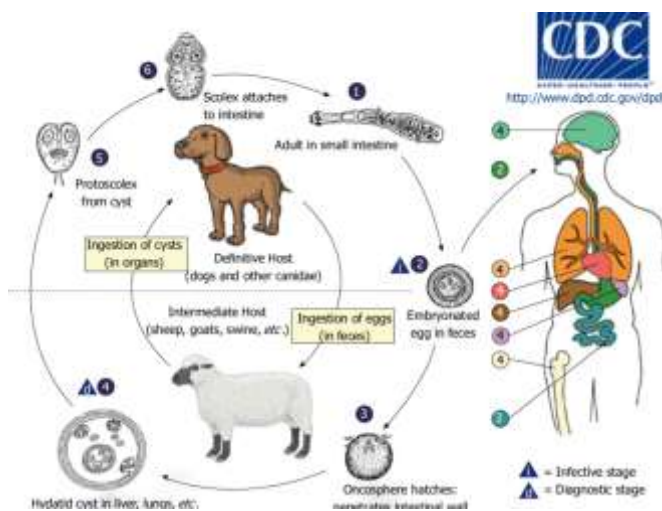


Fig. 2: Life cycle of echinococcus

## Intraoral Complications

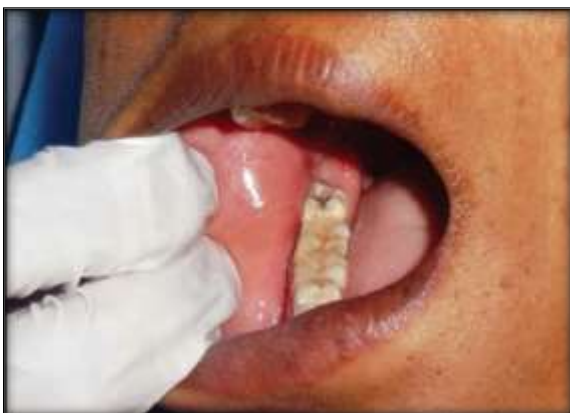

Fig. 3: Hydatid cyst in buccal mucosa

Very rarely these occurs intraorally. First reported in 2000 by Bouckaert et al. by reporting 2 cases of intra oral

hydatid cyst from South Africa.<sup>8</sup> Reported sites are—salivary glands, pterygopalatine or infratemporal fossa areas, tongue, buccal mucosa [Fig. 3], maxillary sinus etc.

Generally these cystic lesions are asymptomatic. The appearance is solitary, well-defined, oval shaped swelling with a bluish translucency. These lesions are slow growing with consistency being soft to firm. They are generally non tender. Sometimes the cysts burst and give a watery discharge. After that they heal on their own but at times recurs as well. Differential diagnosis can be given as-Lymphangioma, mucoceles, if in floor of mouth then ranula [Fig. 4], also benign salivary gland tumours.<sup>6-8</sup>

## Diagnosis

Diagnosis of the cyst is based on patient's history, clinical features, radiological examinations, biochemical examinations and histopathology. Histopathology remains the gold standard for diagnosis.

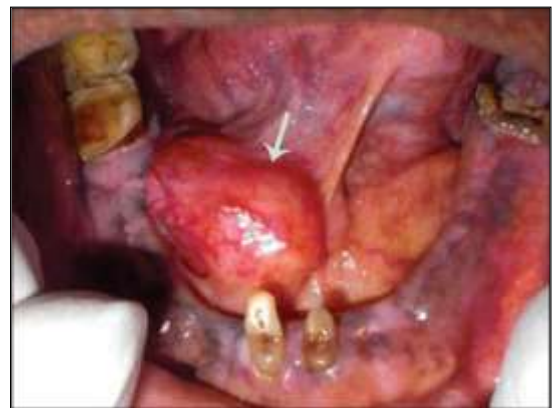

Fig. 4: Hydatid cyst in floor of mouth resembling ranula

One of the tests commonly used is Casoni's reaction. It was introduced by Casoni in 1911. In this test intradermal injection of 0.2ml of a fresh sterile hydatid fluid is injected in suspected patients. If positive it produces a large wheal (5cm in diameter) with multiple pseudopodia within half an hour. This wheal fades within an hour. Sterile 0.2ml of normal saline is injected in the other arm for control. Hydatid fluid is basically used as an antigen.<sup>1</sup>

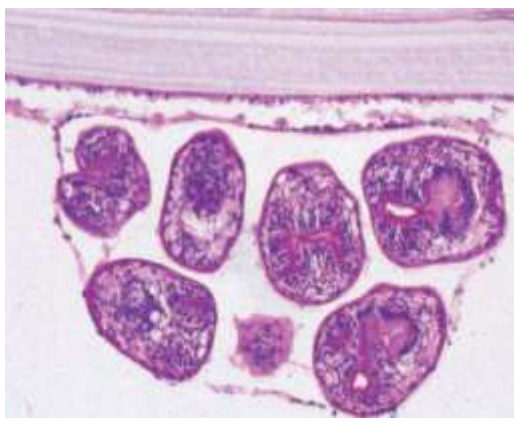Other diagnostic test is exploratory puncture of the cyst to collect the Hydatid fluid and its examination. It is a clear, colourless fluid sometimes may be pale yellow colour. Specific gravity of the fluid is 1.005 to 1.010. It is slightly acidic with pH=6.7. The contents are sodium chloride, sodium sulphate and sodium and calcium salts of succinic acid. The fluid is highly toxic and upon absorption gives rise to anaphylactic symptoms. It is antigenic as well and is used for immunological tests. There is a granular deposit found in the fluid which settles at the bottom. This deposit consists of liberated brood capsules, free scolices and loose hooklets. This deposit is named Hydatid sand.<sup>1,8</sup>

Blood examination is done as well in which 30% of the patients have shown eosinophilia. Serological tests like ELISA, indirect haem agglutination, latex agglutination etc,

have also proved useful in diagnosis in the early period of cystic infection.<sup>7</sup>

The standard intra oral radiographical techniques are of not much help in this regard. However advance imaging techniques like CT, MRI and USG has been helpful in detecting cysts in early stages. USG is helpful when the lesion is cystic in detecting daughter cysts, hydatid sand and hydatid membranes.<sup>6,9</sup>

Histopathology is the ultimate diagnostic aid. Intra oral cysts have shown 3 layers. 1 outer host layer and 2 inner parasitic layer. The host layer consists of fibrous tissue with chronic inflammatory cell infiltration, eosinophil and giant cells. The intermediate layer is white, non-nucleated and consists of many delicate laminations. The inner layer is nucleated germinal layer. The brood capsules or daughter cysts develop originally as minute projections of the germinative layer which further develops central vesicles and forms minute cysts.<sup>8</sup> [Fig. 5]



**Fig. 5: Intermediate and inner germinative layer**

### Treatment

The pharmacological treatment as given by Honor (1989) and endorsed by WHO is Albendazole which is given as 3 cycles each of 28 days course of 10mg/kg/day in divided doses at 2 weeks interval. Praziquantel used as 40-60mg/kg/day doses. Chemotherapy is also advised in younger patients and if cyst is less than 4cm in diameter.<sup>7,10</sup>

Among the non- pharmacological techniques PAIR technique and surgical removal has been given. PAIR (Puncture Aspiration Injection and Reaspiration) is also a good method for the treatment and is widely used around the globe. However the best non pharmacological method is complete surgical removal of the cystic lesion.<sup>1</sup>

### Discussion

The Hydatid cyst are a cystic entity caused by parasite *Echinococcus granulosus*. This infection is also known as Echinococcosis. Hydatid in Greek means 'drop of water'.<sup>11</sup> It is distributed around the globe and affects men and women in equal proportions. Members of canid family like dog, wolf, fox etc. being the primary host for the parasite whereas cattle and human beings are the intermediate hosts. Its is mainly concentrated in areas of Africa, New Zealand, Central Europe, South America and Middle East Australia.<sup>9</sup> The

incidence of Hydatid cyst in India is 1-200/1,00,000 population mostly in Kashmir, Andhra Pradesh, Gujarat and Tamil Nadu.<sup>12</sup>

The infection is mostly localised in liver and lungs (80%). It also has been reported in peritoneum (20%), spleen (0.7-8%), kidney (7%), skin and muscles (4%), nervous system (0.2-3%), bones (2%), heart (0.2-2%).<sup>13</sup>

In the head and neck region its incidence is estimated about 1-2%. Very limited cases of intraoral hydatid cysts have been reported in the clinical literature. Intraoral locations are very unusual for this cystic entity.<sup>7</sup>

Surgical excision is always the treatment of choice but WHO has given a pharmacological regimen as well which is also effective.

### Conclusion

This entity being very rare in the intraoral region is a curious and interesting thing for the diagnosticians. Proper knowledge of parasitology is needed by the clinicians for the proper diagnosis of such entities. Failure to diagnose can lead to deviation from the path of proper treatment.

**Conflict of Interest:** None.

### References

1. Chatterjee KD. Parasitology. 13th edition. 2015; India.
2. Kirmani MA, Sajad M, Patigaroo AR, Khan AR. Hydatid cyst of tongue. *JK Pract* 2007;14:107.
3. Umesh K, Sulabha AN, Sameer AC, Neelakant MW, Sangamesh NC, Ali RP. Hydatid cyst of infratemporal region - A rare case report. *J Med Sci* 2010;3:94-98.
4. Berkiten G, Topaloglu I. Submandibular hydatid cyst fistulized into the oral cavity. *B-ENT* 2013;9:251-3.
5. Nayar RC, Rajwanshi A, Menn SB, Arora MM. Hydatid cyst in the floor of the mouth. *Indian J Otolaryngol* 1982;34:78-9.
6. Alaparthy KR, Yelamanchili S, Nunsavathu NP, Sode U. Intraoral hydatid cyst a rare case report. *JIAOMR* 2015;27(3):1-8.
7. Lavanya RM, Kamath VV, Komali Y, Krishnamurthy S. Hydatid cyst of buccal mucosa: an unusual presentation. *Indian J Dent* 2015;6(3):157-60.
8. Shear M, Speight P. Cysts of oral and maxillofacial regions. 4th edition. 2007; England.
9. Scherer P, Mischkowski RA, Seifert H, Ortmann M, Neugebauer J, Scheer M, et al. Solitary hydatid cyst in the mandible: Case report and review of the literature. *J Oral Maxillofac Surg* 2008;66:1731-1736.
10. Soylu L, Aydogan LB, Kiroglu M, Kiroglu F, Javadzadeh A, Tuncer I, et al. Hydatid cyst in the head and neck area. *Am J Otolaryngol* 1995;16:123-5.
11. Bouckaert MM, Raubenheimer EJ, Jacobs FJ. Maxillofacial hydatid cysts. *Oral Surg Oral Med Oral Pathol Oral Radiol Endod* 2000;89:338-42.
12. Aggarwal N, Panja T, Biswas K, Kar T. Hydatid cyst of tongue: a diagnostic challenge. *BJOJNS* 2017;25(3):171-2.
13. Saez J, Pinto P, Apt W, Zulantay I. Cystic Echinococcosis of the tongue leading to diagnosis of multiple localizations. *Am J Trop Med Hyg* 2001;65:338-40.

**How to cite this article:** Jha CS, Sinha R, Sen S, Jha H. Intraoral hydatid cyst: A review. *J Oral Med, Oral Surg, Oral Pathol, Oral Radiol* 2019;5(1):4-6.